

**Simone Caramel**

**Auscultatory Percussion of the Stomach.**

**according to Sergio Stagnaro**

**Auscultatory Percussion Reflex Diagnostics  
the cardio-gastric aspecific reflex**



**Handbook**

**QBS Journal Press**

## INDEX

PREFACE.....	3
INTRODUCTION.....	4
<b>Part I. Auscultatory Percussion of the Stomach according to Stagnaro.....</b>	<b>12</b>
CHAPTER 1. Step 1. Position of the patient.....	12
CHAPTER 2. Step 2. Position of the stethoscope .....	13
CHAPTER 3. Step 3. Auscultatory Percussion .....	16
CHAPTER 4. Step 4. Delimitation of the stomach .....	22
<b>Part II. Auscultatory Percussion Reflex Diagnostics .....</b>	<b>26</b>
CHAPTER 5 Step 5. Auscultatory Percussion in Reflex Diagnostics.....	26
CHAPTER 6. Step 6. Stimulation of the trigger-points of interest .....	30
CHAPTER 7. Step 7. Trigger-points: magnitude of the stimulation .....	33
CHAPTER 8. Step 8. Intense stimulation of trigger-points: the simultaneous reflexes..	34
CHAPTER 9. Step 9. Mean stimulation of trigger-points: the cardio-gastric reflex.....	37
9.1 Latency time of cardio gastric reflex in Gentile's sign.....	38
9.2 Duration of cardio gastric reflex in Gentile's sign.....	42
9.3 Intensity of cardio gastric reflex in Gentile's sign.....	44
9.4 Differential latency time of cardio gastric reflex in Gentile's sign.....	46
9.5 Tonic gastric contraction of cardio gastric reflex in Gentile's sign.....	48
9.6 Summary.....	48
APPENDIX A The mathematical relations between the different parameters.....	51
APPENDIX B IRR of CAD with predisposition to AMI and without any risk of AMI.....	53
APPENDIX C Maneuvers to exclude the 'false negative' cases.....	55
REFERENCES .....	55
VIDEO REFERENCES.....	58
OTHER SOURCES.....	58

## PREFACE

This monograph was born from a brilliant idea of a genius, the President of SISBQ, Dr. Simone Caramel, the most refined connoisseur, and excellent writer of the Quantum-Biophysical-Semeiotics.

Really, at the beginning I judged such an enterprise as Promethean one, but embraced it with courage for a fundamental reason, promising to Simone my total support in preparing the written part of the Monograph. As a matter of fact, ever since I have considered that the 'Gastric Aspecific Reflex' plays a central role in the Quantum Biophysical Semeiotics, so that physicians must familiarize with it, wanting to become an expert in this discipline.

The large number of valuable figures, of excellent beauty and effectiveness, from the hermeneutical view-point, will help the reader in learning the basic concepts of the 'Gastric Aspecific Reflex', and then in bedside applying this important tool for the diagnosis, therapeutic monitoring, and clinical research.

I feel entitled to state that physicians can enter into the QBS, only if they know perfectly the 'Gastric Aspecific Reflex'.

Since QBS is an original interdisciplinary science, continuously evolving, and expanding its boundaries, at beginning of the study, surely, physicians can encounter difficulties during their learning, only apparently hard to overcome. However, I am sure that the careful reading of this Monograph, will make them understand that "The difficult in today's will be routine in tomorrow."

*Sergio Stagnaro*

## INTRODUCTION

"I feel (to say) that the four cardinal points in the physical diagnostics (we thought) - inspection, palpation [1], percussion and auscultation - a fifth should be added: Auscultatory Percussion [2, 3]" (personal communication between John R. Guarino and Sergio Stagnaro, 1982, Figure a).

John R. Guarino  
March 24, 1982  
Associate Professor of Clinical Medicine  
University of Washington  
BOISE V.A. Medical Center

To Dr. Sergio Stagnaro

Dear Colleague ,

I would like to thank you for your letter of 5 October 1981 I received recently .

Congratulations ! I am impressed by your article and by the intense work that you have done in the auscultatory percussion (AP) . Among other things, your English is excellent and far exceeds my Italian - a regrettable deficiency that I dare not reveal.

I agree that your new methods that you describe so well in your article "Reassessment and new developments of a fundamental diagnostic method : the Auscultatory Percussion " uses the same basic principles and are an important contribution to physical diagnosis .

AP is an important diagnostic technique , and it's really unfortunate that it is virtually ignored from Laennec . As you know, it is rarely mentioned in the texts, and literature in schools. I feel ( to say ) that the four cardinal points in the physical diagnostics ( we thought ) - Inspection , palpation , percussion and auscultation - a fifth should be added: Auscultatory Percussion .

Included are some excerpts that may be of interest . The technique ( applied ) to the urinary bladder is now used routinely in our hospital before catheterization , and is intended for patients with nervous bladders , self - catheterization.

A case series of 89 patients studied with the head of the AP to recognize intracranial masses will soon be published in the British Medical Journal. I'll be happy to send you a statement .

I would appreciate an extract of his monograph to be published by Farmitalia and the Ligurian Academy of Science and Letters .

With the hope to receive soon,  
a cordial greeting to you

Signed by hand.  
John R. Guarino

Figure a. Letter sent from John R. Guarino to Sergio Stagnaro in 1982

The combination of auscultation and percussion was given a second youth by Guarino [4] under the name "Auscultatory Percussion" (AP).

We remember that there are three ways to percuss the patient:

1) comparative<sup>1</sup> percussion (the original method of Auenbrugger and Laennec); 2) topographic<sup>2</sup> percussion (invented by Piorry of France in 1828); 3) Auscultatory<sup>3</sup> Percussion (introduced by the Americans Camman and Clark in 1840).

<sup>1</sup> Comparative percussion identifies disease by comparing the right and left sides of the chest. Prominent dullness or unusual hyper-resonance over one side indicates disease in the part. Bilateral disease, by definition, is more difficult to identify using comparative percussion.

<sup>2</sup> Topographic percussion attributes any dullness in the chest or abdomen to airless intrathoracic tissue lying directly beneath the percussion blow. Topographic percussion differs from comparative percussion in implying that the clinician can precisely outline the borders of underlying organs and then measure their span. The technique is still used today to measure excursion of the diaphragm (and to identify and enlarge heart or liver). When using topographic percussion to determine diaphragm excursion, the clinician locates the point of transition between dullness and resonance on the lower posterior chest, first during full inspiration and then during full expiration. The diaphragm excursion is the vertical distance between these two points. The reported normal excursion of healthy persons ranges from 3 to 6 cm. (For comparison, the corresponding excursion on the chest radiograph is about 5 to 7 cm in normal persons and 2 to 3 cm in patients with lung disease).

There are three percussion sounds – tympany (normally auscultated over the abdomen), resonance (auscultated over a normal lung) and dullness (auscultated over the liver or thigh). Tympany differs from resonance and dullness because it contains vibrations of a dominant frequency that allow the clinician to actually recognize its musical pitch. Resonance and dullness, in contrast, are “noise” in an acoustic sense, consisting of a jumble of frequencies that prevent identification of a specific musical pitch. The three sound characteristics distinguishing resonance and dullness are intensity, duration, and frequency content: resonance is louder and longer and contains more low-frequency energy. Of these three sound characteristics, clinicians appreciate most easily that resonance<sup>4</sup> is louder than dullness.

Today most clinicians use the indirect method with comparative and topographic percussion and the direct method with Auscultatory Percussion.

The combination of both auscultation and percussion in the diagnostic examination improves both auscultation and percussion and, in so doing, increases the skill of palpation [1]. The Auscultatory Percussion [5] is mostly unknown in the modern medicine: it was learned in Italian Universities till the third decade of last century, but in some country, as in Russian Federation it is still practiced, i.e., in the way of friction.

Very few scientists studied and applied this technique in the last decades: we remember two of them (Figure a): Prof. John R. Guarino in United States [6-12] and Dr. Sergio Stagnaro [13-23] in Italy.

What is Auscultatory Percussion (AP)? Invented and firstly described briefly by Leopold Auenbrugger, AP was fully described by Laennec and was used to outline solid organs (Norris and Landis, 1938). The stethoscope was placed upon the part to be investigated, and the examiner listened while percussing from the periphery toward the chest piece. The sound became distinctly louder when the boundary of the organ was reached. The principle of AP was developed for the detection of the size of heart, liver, spleen, kidney, bone fractures, ascites, and pleural effusion (Cammann and Clark, 1840) but seems to have been lost. There seems to be no recognition of the common history by authors who

---

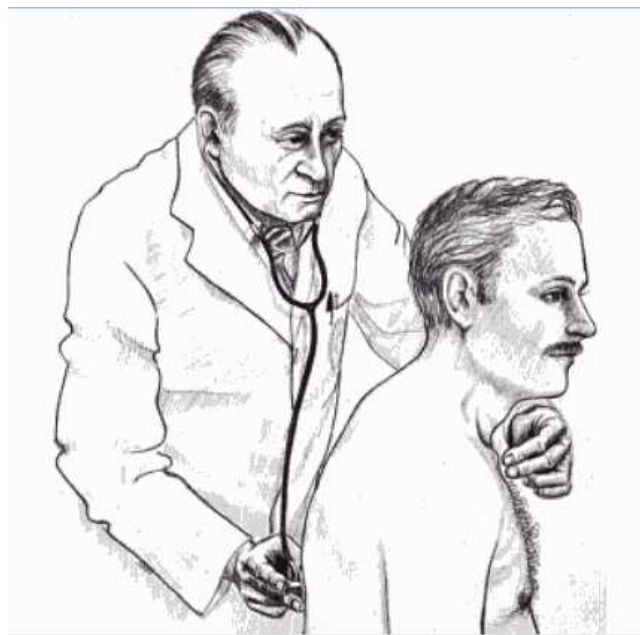
<sup>3</sup> Auscultatory Percussion was introduced to further refine the goals of topographic percussion. Instead of listening to sounds as they resonate off the chest into the surrounding room, the clinician using Auscultatory Percussion places the stethoscope on the body wall and listens through it to the sounds transmitted by nearby percussive blows. Over the past 150 years, Auscultatory Percussion of the chest has repeatedly fallen out of favor and then resurfaced as a “new sign”. In the most recent version of Auscultatory Percussion of the chest (Guarino, 1974), the clinician taps lightly over the manubrium and listens over the posterior part of the chest with the stethoscope. Using this technique, the clinician should find identical sounds at corresponding locations of the two sides of the chest; a note of decreased intensity on one side supposedly indicates ipsilateral disease between the tapping finger and the stethoscope. The technique of using Auscultatory Percussion to detect pleural fluid, first developed in 1927, is slightly different. The clinician places the stethoscope on the posterior chest of the seated patient, 3cm below the twelfth rib, and percusses the posterior chest from apex to base. At some point, the normal dull note changes to an unusually loud note: if this occurs with strokes above the 12<sup>th</sup> rib, the test is abnormal, indicating pleural fluid. Each percussion blow should strike the same part of the pleximeter with identical force, and the pleximeter finger should be applied with the same force and orientation when comparing right and left sides. Consistent technique is important because both the percussion force and the pleximeter govern the percussion sound produced. Lighter strokes produce sounds that are duller than those produced by stronger strokes. Lifting the pleximeter finger, even slightly, can transform a resonant note into a dull one. Even though a consistent technique is important, the force and speed of percussion blows vary threefold among different clinicians, which probably explains why interobserver agreement for topographic percussion is poor compared with that for other physical findings. The traditional teaching is that the plexor finger should be promptly withdrawn after a blow, mimicking the action of a piano key striking a string. The only study of this found that clinicians could not distinguish the note created by a rapid withdrawal from one in which the plexor finger lightly rested on the pleximeter after the blow.

<sup>4</sup> Some clinicians take advantage of resonance being louder than dullness and apply a technique called threshold percussion, in which percussion blows are so light that dull areas produce no sound. As the blows move along the body wall with precisely the same amount of force, a note abruptly appears the moment the blow encounters a resonant area.

appear to have rediscovered such a technique on their own (for instance, see Webb's 1927 utilization of the technique for pleural effusion; the various "scratch" tests for cardiac and hepatic size; the "puddle sign" of ascites; and the Gairdner coin test).

In the modern era, Guarino developed Auscultatory Percussion techniques for the chest [6, 7], as well as for the head [9], urinary bladder [8, 10], and abdomen. Using polyurethane models of the thorax, he claimed that the technique could locate small deep parenchymal masses. Guarino's original method was designed to look specifically for pleural effusions [12] and it is described as follows:

a) with the patient sitting or standing, physician has to percuss directly over the manubrium by tapping lightly with a fingertip (the rationale given for striking the manubrium was to avoid "the interfering effects of the left ventricle" especially when the latter is enlarged);  
b) auscultate the tapping sound by placing the stethoscope diaphragm on the posterior thorax (Figure b); compare the sounds on the two sides, moving from top to bottom, no more than the diameter of the diaphragm each time; c) complete the examination by placing the diaphragm piece on opposite sides of the spinal column to detect hilar and mediastinal lesions. Take care not to overread the changes<sup>5</sup>.



*Figure b. Auscultatory Percussion of the chest by JR Guarino*

Guarino's results were extremely impressive and did much to reawaken interest in this technique. In a series of 30 patients with varying abnormalities of the lung, mediastium, or pleura but negative or equivocal findings on conventional percussion, he claimed a

---

<sup>5</sup> When learning and teaching Auscultatory Percussion, it is strongly recommended that the maneuver be subjected to the most critical scrutiny. You can do it by having the student auscultate posteriorly while the teacher taps on the chest anteriorly with his eyes closed so that he cannot know which side of the chest the student is auscultating. It is very easy to unconsciously modify the intensity of the blow; in fact, it is very difficult to strike exactly the same blow every time. Accordingly, one must be especially aware of the observer effect (the unconscious tendency for the observer to produce the effect he desires). Musicians who play percussion instruments must be particularly careful to have their finger strike through an excursion of the same distance and force each time (many percussion instrument players adjust their hand stroke to produce a constant sound intensity without being aware of it!). A lesion is said, by Guarino, to cause an area of dullness "like casting a shadow".

sensitivity of 0,96. He was able to detect smaller lesions (e.g., a.5 cm pulmonary nodule) than can be detected by conventional physical examination [7].

In parallel with Guarino's studies (Figure a), Stagnaro developed his research and experiments with Auscultatory Percussion from the 50<sup>th</sup> of last century, publishing his first results in the second half of 70<sup>th</sup> [13].

Since 1955, Stagnaro has reviewed and developed the ancient "art" of medical Auscultatory Percussion.

In 1970 he gave rise to the Auscultatory Percussion Reflexes Diagnostics and exploring the non-linear dynamics of biological systems, whose behavior is physiologically deterministic chaotic, he founded the original Biophysical Semeiotics.

In 1977 he published his first work [13]. In 1978 he wrote the book "Nuovi Aspetti di Semeiotica Medica" ("New Aspects of Medical Semiotics"). In 2004, the book "Introduzione alla Semeiotica Biofisica. Il Terreno Oncologico" was published [22]. In the first part of the tome the original diagnostic method based on percussion and auscultation of viscera and organs is described in details.

'Auscultatory Percussion Reflex Diagnostics', is the dynamic part of the method. For the benefit of the reader, just know that the first method of investigation (Auscultatory Percussion) shows the contours of a viscera, such as the stomach, but with the latter one we can create reflexes, which change the dimensions of the various biological systems: a static survey (the first one) and, respectively, dynamic, much more rich in information the second one. Only since 1990, the new method achieved the original and revolutionary characteristics own of Biophysical Semeiotics.

The 'Auscultatory Percussion', as re-interpreted by Stagnaro, is founded on the principle that the human body is the paradigm of a complex and wonderful system information, sent from side to side of the body, in physiological and especially pathological conditions, transmitted in the form of nerve in-puts, caused by stimuli of physical, chemical, vascular, biochemical and metabolic nature, able to activate histangic or tissue receptors, beginning of reflex arcs ending in many viscera and organs.

With the help of this method, born in the late eighteenth century, the physicians evaluate, both qualitatively and quantitatively, the changes in the target organs of an individual who stays in a supine position and psycho-physically relaxed, according to well-defined ways of stimulation and auscultation.

The 'Auscultatory Percussion' embodies the idea that reality, in physiology and pathology, but also his knowledge, is the relation between the single entities (physician's mind and senses and the patient's body) on the basis of information contained within the bodies themselves, exchanged between entities to form a structure that connects and penetrates everything." As Gregory Bateson says 'That wider knowledge', 'Glue that holds together the stars and anemones' is present inside both the one and others.

The mind is a relational phenomenon within single entities and between different entities, present where there is information, 'difference that causes a difference', a stimulus that changes its receptor and generates in-puts that are transmitted along the afferent neuron related to the nervous centers and then to the efferent neuron to cause a difference in the way of being of the trigger (target) organ. Faced with this complexity and structure dynamics to know, it is clear that the whole is far greater than the sum of its parts, beyond

the typical approach still reductionist 'dividi et impera' of the simply deterministic current scientific method. The correct approach or cognitive model must necessarily be complex, molecular-biological, globally comprehensive and non-reductive, meaning not to exclude the simple and predictable one from the complexity, which is indeed included, but accepting the challenge that the word (problem) complexity implies and means: to prefer the path and not the final goal, but obviously ongoing way-points can be reached in, which are at the same time goal-starting points for further adventures of ideas.

Left the hospital and returned to Riva Trigoso, the young Stagnaro is left with only the stethoscope in his hand and a universe yet to be discovered. He continues like this for years to practice in the exploration and appreciation of the ancient art of 'Auscultatory Percussion', static method of auscultation of individual organs, but adding a key element, namely the desire to observe the biological systems dynamics, finally realized in 1970 and baptized the 'Auscultatory Percussion Reflex Diagnostics'. Dynamics is due to the fact that you can modify these biological systems through reflexes causing and by means of AP you can see the changes. In 'Auscultatory Percussion' there are three successive moments equally important: the production (by direct percussion of delicate intensity above the skin), the transmission (through tissues of different acoustic impedance) and auscultation of sound waves (with the help of the stethoscope). The 'Auscultatory Percussion Reflex Diagnostics' is based on data provided by AP and in particular on the reflexes, both physiologically and primarily pathological. These are skin, muscle and viscera-visceral reflexes caused due to manual stimulation of interest trigger-point that offer quantitative and qualitative parameters of fundamental diagnostic value for the evaluation. The example provided below can help to a better understanding of the maneuver. The part of the viscera more appropriate and easier to delimit for an AP is the greater curvature of stomach.

Through Quantum Biophysical Semeiotics (QBS) method we can evoke reflexes by striking the spleen, heart, liver, bile duct, blind, ureters, but the stomach has always had a special fascination for Stagnaro.

In the grip of a strong emotion an individual complains of stomach pains. Between each part of our body, which I have always considered as the best among the existing cybernetic structure that may have been created by the Good God, there must be a correlation, a structure made of reflexes transmitted by the nervous system and, perhaps, "channels energy "or more, at the time little known, which originated in the most different points from each other, they end up, in technical terms, they "close" in the stomach<sup>6</sup>.

These safe events are explained by the fact that the stomach is regulated by two gastric nerve plexuses, upper and lower, in their turn dependent on the solar plexus or celiac. Solar, you see, because it is in the center of the 'universe' man. It was then discovered, in the sixties, the 'Gastric Aspecific Reflex', the changes that occur in the stomach, spontaneously in appendicitis, renal colic, hepatic colic, but also caused by the physicians, iatrogenic.

---

<sup>6</sup> Benedict described another form of sounds for diagnostic purpose to determine the degree of acidity in the gastric contents. He artificially made the sounds by introducing bicarbonate of soda into the stomach, which on contact with the acid causes the sound of effervescence (from Ismar Boas, 1907, mentioning the Auscultatory Percussion of the stomach).



From the practical point of view, the application of Auscultatory Percussion consists of three successive moments equally important for the proper execution, and expression of the internal and external consistency of the method:

- a) **Production of sound waves** by "direct" and slight percussion on the skin, with the middle finger slightly bent as a hammer;
- b) **Transmission of sound waves** through tissues of different acoustic impedance;
- c) **Auscultation of the sound waves** so caused and transmitted, with the help of the stethoscope.

The Auscultatory Percussion (AP) is a "listened pat" and must be necessarily delicate in order to obtain a correct and optimal execution.

The lines of percussion are parallel when you want to define a linear margin (i.e., lower or liver's border), while they are radial and centripetal if the bowel to demarcate is rounded (i.e., stomach's border).

In the **production of the sound waves** you always goes from the outside to inwards in such a way that these waves move away from the skin to the internal body, chest or abdomen, following straight lines that are perpendicular to the surface, without undergoing refractions, before meeting the structures to investigate, then they return, after reflection, to the drum of the stethoscope, along perpendicular paths themselves. It is important that the intensity of the percussion is mild, delicate, never intense. Indeed, if it was an intense percussion, the AP sound would be perceived before it was beaten the skin projection's area of the organ or viscera to be examined. This improper percussion would have, as inevitable consequence, a misjudgment excess of the diameter or size of the structure to be investigated. In other words, the geometry of the slight percussion is rightly the Euclidean one, while that of the erroneously intense percussion is a projective geometry, that is incorrect for the purposes of diagnosis.

The **transmission of sound waves** through different structures depends on the different and characteristic acoustic impedance, following the laws of physics. The intensity of the interference that the wave encounters in passing from one medium to another, contiguous and of different impedance, is related to the magnitude of the difference itself, i.e, between air and water it is considerable ( only 0.1% of sound's energy penetrates the air-water interface, while 99.9% is reflected or refracted). The AP method is founded on these principles of physics. Concepts that are well known to geophysicists in the study of earth layers, such as about acoustic impedance, are now applied to the AP method.

The third and final step of Auscultatory Percussion is represented by the **Auscultation of the sound waves**, i.e., the AP sound collected from the drum of the stethoscope, artfully placed.

The drum of the stethoscope is in direct contact with the skin and is held in place by a finger of the patient, who thus actively participates, seeking for signs and reflexes. The patient becomes an active player during the semiotics visit, and in this way we are re-evaluating the relationship physician - patient, proper and peculiar to 'Single Patient Based Medicine' [23].

Sound waves collected by the drum of the stethoscope, that is the ear's extension of the physician, are perceived distinctly different, according to the quality and intensity, in relation to the seat of the digital percussion, directly on the skin and gently performed.

When the points, on which the percussion it is applied, are outside the cutaneous projection of the organ or viscera to be examined, the sound is perceived as 'originated away from your ear ', of very weak intensity, indistinct and generally clear. In contrast, intensity and timbre of the sound are completely changed when the striking finger is approaching the border of the skin projection of the structure / organ to be examined. In the latter case, the sound is perceived intense, clean, clear; i.e., investigating the stomach, it is 'as born near the ear of the listener '. By this way, it allows to evidence distinctly the change of the sound when the percussion falls upon the exact skin projection of the investigated structure.

When the sound is perceived to be amended so that "it seems to come close to the ear of the listener", the physician should consider that point as belonging to the border of the real skin projection of the bowel or organ to be examined, according to the spirit of the Euclidean geometry.

The Auscultatory Percussion (AP), as well as revised by dr. Sergio Stagnaro, is the basis of Auscultatory Percussion Reflex Diagnostics (APReD), founded by the same Ligurian scientist, that allows the evocation of original biophysical semeiotics reflexes. These are reflexes, both physiological or pathological , of type skin - , muscle - , and viscera - visceral, evoked in various ways with manual, digital and nail pressure, and by prolonged pinch of varying intensity, at the level of several trigger-points , according to precise execution modes. These reflexes, so evoked in many viscera, offer several quantitative parameters to the evaluation, useful both for diagnosis and therapeutical monitoring.

With the help of the AP signs, the physician assesses size, tone, elasticity, contractility, segmental or global, of viscera. All these signs are very interesting from the point of view of diagnosis and differential diagnosis .

The aspecific gastric reflex , in-depth in this monograph, is a reflex evoked as a result of the Auscultatory Percussion of the stomach and it becomes however specific, when it is placed in a specific context, that is when the stimulated trigger point is known.

This handbook consists of 9 chapters aimed at teaching practical physicians (especially General Practitioners) who want apply the AP of the stomach. In particular, we detail the evocation of one type of gastric reflex: the cardio - gastric aspecific reflex. Three appendices deepen three particular aspects of the gastric reflex: its correlation with the information that you get from ureteral reflex and the related 'Clinical Microangiology' [24], mediated by the fractal dimension measure, invariant statistic of non-linear dynamics and deterministic chaos, a recent discovery that allows the differential diagnosis of Inherited Real Risk of coronary artery disease (CAD) with or without predisposition to acute myocardial infarction (AMI) and some stress tests to dissipate the 'false negative' cases.

The first part of the handbook explains the AP of the stomach , as well as described by Stagnaro. It includes four chapters, at the end of which the doctor is already able to make the whole delimitation of the stomach. In the first chapter (step 1) in the correct position of the patient is explained; in the second (step 2) the position of the stethoscope is detailed; in the third (step 3) the auscultatory percussion technique is explored; and in the fourth (step 4) the demarcation of the stomach is finalized.

The second part of the handbook (from chapter 5 to chapter 9) is dedicated to the 'Auscultatory Percussion Reflex Diagnostics (APReD): in chapter 5 (step 5); the

Auscultatory Percussion technique in the Reflex Diagnostics; in chapter 6 (step 6) the stimulation of the trigger points of interest; in chapter 7 (step 7) the intensity of the stimulus on the trigger points , in chapter 8 (step 8) the intense stimulation on trigger points of interest, i.e., the skin projection of the precordium and the simultaneous reflexes (i.e., the Caotino's sign) , in chapter 9 (step 9) the stimulus of mean intensity on the trigger points of interest, i.e, upon the skin projection area of the precordium, and the cardio - gastic aspecific reflex (Gentile's sign) .

The appendix A highlights the relations between the different parameters, collected with the evocation of the gastric aspecific reflex, and their relation with the fractal dimension and the microcirculatory functional reserve. In appendix B the particular case of the differential diagnosis of the inherited real risk of coronary artery disease (CAD) with or without congenital predisposition to Acute Myocardial Infarction (AMI) is analyzed in detail. Appendix C is dedicated to the stress tests the physician must always perform during every QBS diagnosis, in case of negative signs, in order to dissipate the 'false negative' cases: 10-15% of negative patients at first evaluation are 'false negative'.

## Part I. Auscultatory Percussion of the Stomach

### Chapter 1.

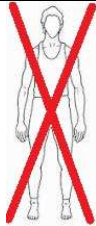





#### Step 1. Position of the patient



Figure 1

The patient lies in a supine position, psycho-physically relaxed, with **open eyes** to reduce the secretion of melatonin (Figure 1).

#### Step 1. Common mistakes – wrong behaviors

Situation	Error – wrong habit - NO	Correct situation - YES
Patient's position	 Standing position	 Supine position
Patient's eyes	 Closed Eyes	 Open Eyes
Patient's psychology	 Nervous	 Psycho-physically relaxed

## Chapter 2.

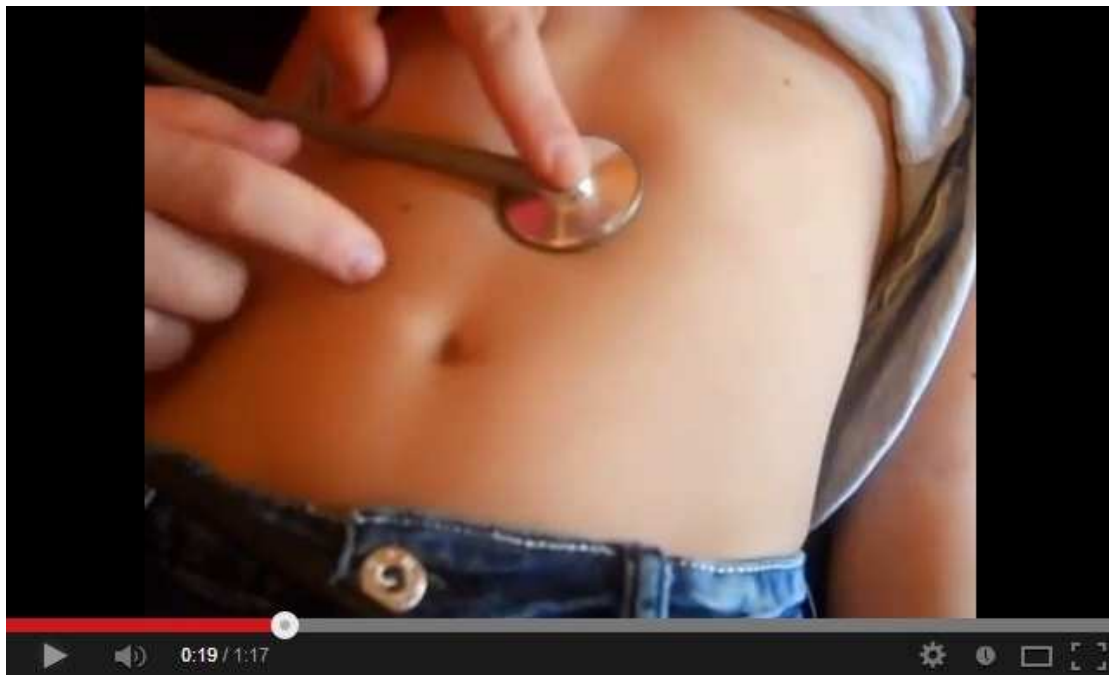### Step 2. Position of the stethoscope



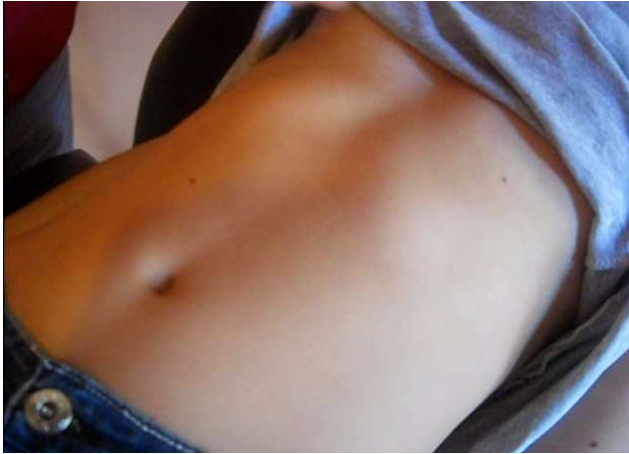Figure 2

Summary: The patient helps the physician holding the drum of the stethoscope on the skin projection of the organ (i.e., the stomach) percussed with a finger-pulp (Figure 2). In the case of gastric aspecific reflex, **the drum of the stethoscope is placed on any point of the skin projection of the stomach.** To be sure to locate the stethoscope on the skin projection of the stomach (depending on the different patients, the stomach is positioned in different ways, i.e., with diverse shapes and sizes) you can follow the below procedure. The drum of the stethoscope stays there for all the time of the diagnosis.

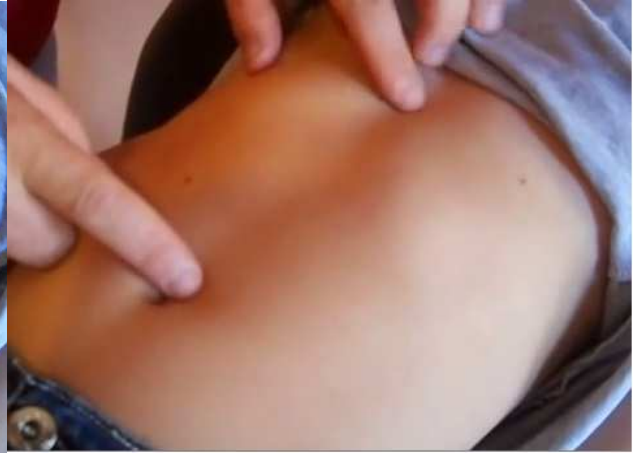- a) Place the stethoscope on the skin projection area of the stomach: on the xipho umbilical line, below the ensiform appendix, 2-3 cm below, 1-2 cm to the left (Photograms 2.1, 2.4); (see position of the stethoscope: in the video



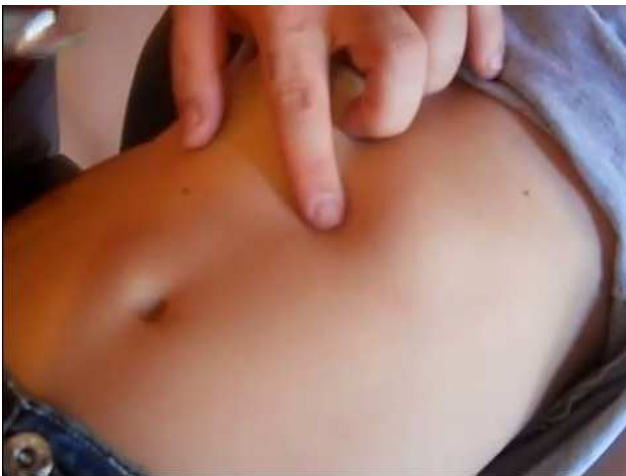<http://www.youtube.com/watch?v=Y2MWsbnFfMc> from 0 sec. to 15 sec.);



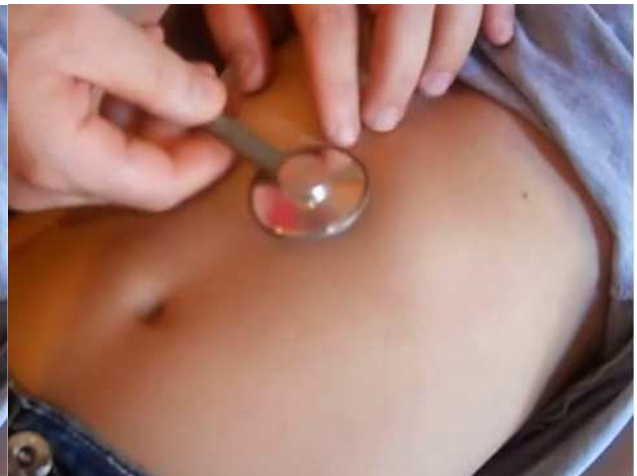*Photogram 2.1*



*Photogram 2.2*

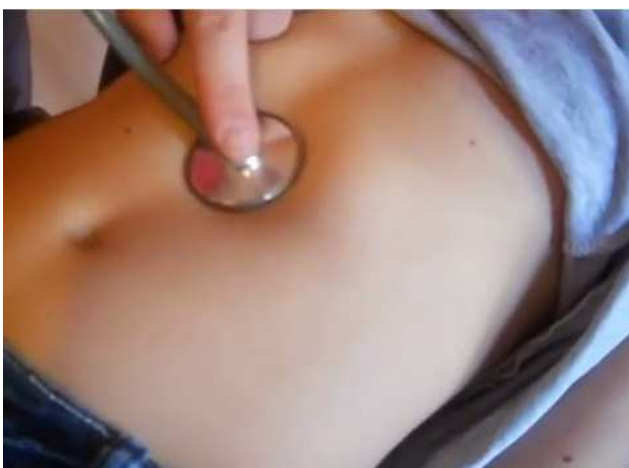

*Photogram 2.3*

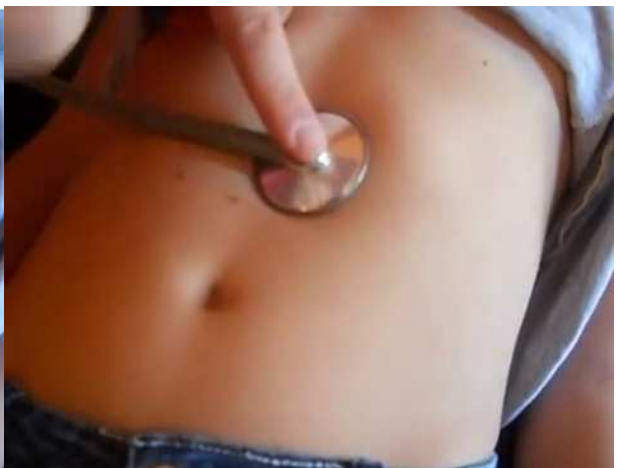

*Photogram 2.4*

b) Ask the patient to support the stethoscope with a **light pressure**, so to ensure **complete adhesion of the membrane to the skin** (Photograms 2.5, 2.6).


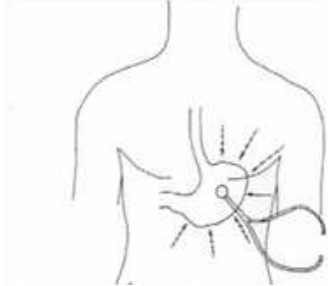






*Photogram 2.5*



*Photogram 2.6*

**Step 2. Common mistakes – wrong behaviors**

Situation	Error – wrong habit - NO	Correct situation - YES
Stethoscope's position	 <p data-bbox="491 660 970 734">Outside stomach's skin projection area</p>	 <p data-bbox="1093 611 1396 685">Inside stomach's skin projection area</p>
Stethoscope's adherence	 <p data-bbox="502 1025 960 1099">Not fully skin's adherence of the drum</p>	 <p data-bbox="1040 1025 1449 1099">Fully skin's adherence of the drum</p>
Stethoscope's pressure & finger	 <p data-bbox="480 1361 983 1480">Finger pulp vertical to the body; too much pressure on the drum of the stethoscope</p>	 <p data-bbox="1046 1361 1445 1473">Finger pulp parallel to the body; slight pressure on the drum of the stethoscope</p>

## Chapter 3.

### 3. Auscultatory Percussion

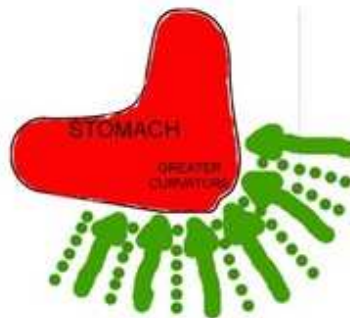


Figure 3

When you start the percussion (for the delimitation of the stomach) with a finger pulp, you don't know, at the beginning, where is the border of the stomach, so you start to make a percussion from very below of the stomach (from the right iliac crest - cavity - from external) towards the drum of the stethoscope (Figure 3a), just listening to the sound you are hearing in your ear; it is like you are walking with your finger, following radial and centripetal lines, as evidenced in figure 3 (the lines you are walking on with your finger are marked by green dots (Figure 3, 3b), the green arrows 8 (distanced about 1cm each other) mark the direction you are following, from external to internal, centripetal and radial, Figure 3, 3a). At the end of each line, of each walk (see Photogram 3.1-3.16), you draw with a marker a black dot on the point in which the sound changes (Photogram 3.16). This step of demarcation will be explored in depth later (see step 4, demarcation of the stomach).

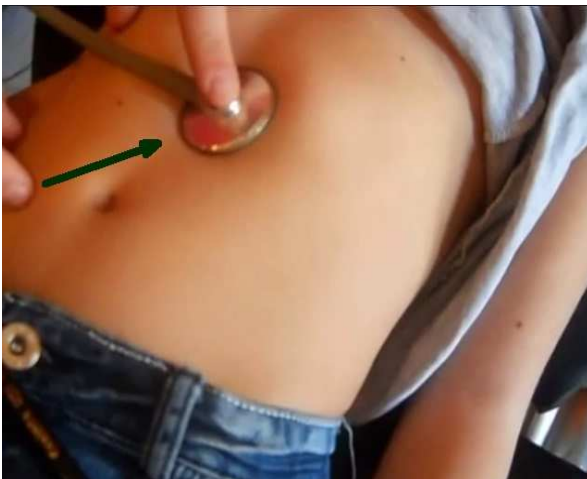


Figure 3a

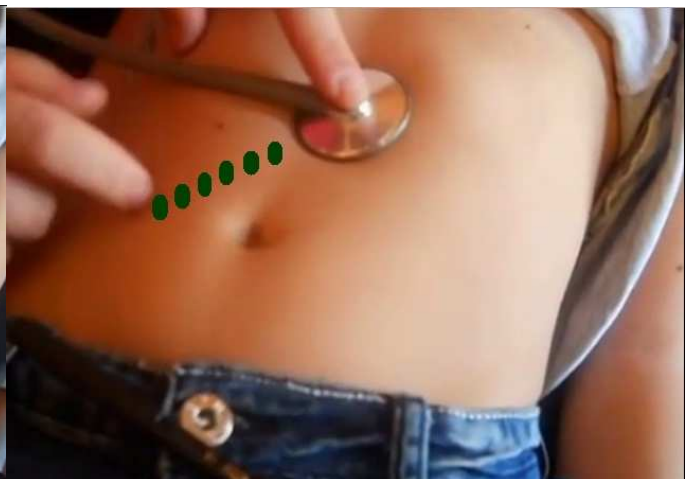
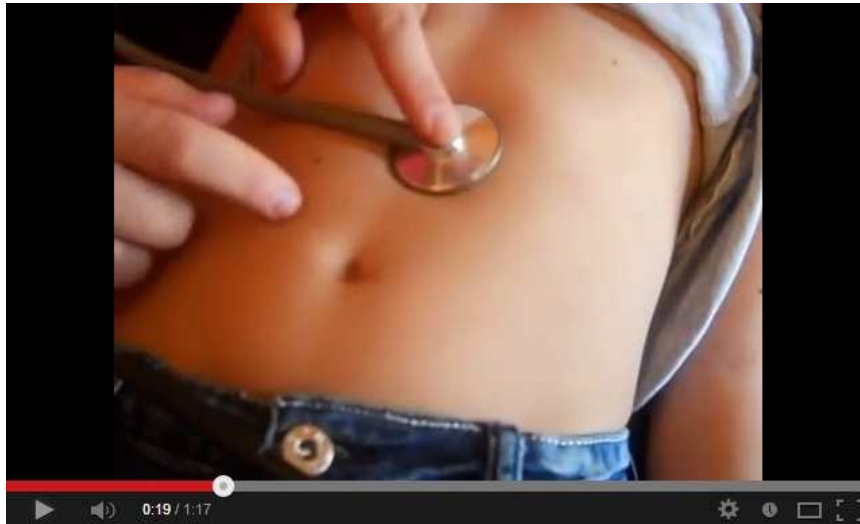
Figure 3b

See below the photo sequences (Photograms 1-16) of the percussion of one line (Figure 3a, 3b) finalized to mark the first dot of the border of the stomach, taken from the video [from sec. 15 to sec. 21]:





<http://www.youtube.com/watch?v=Y2MWsbnFfMc>

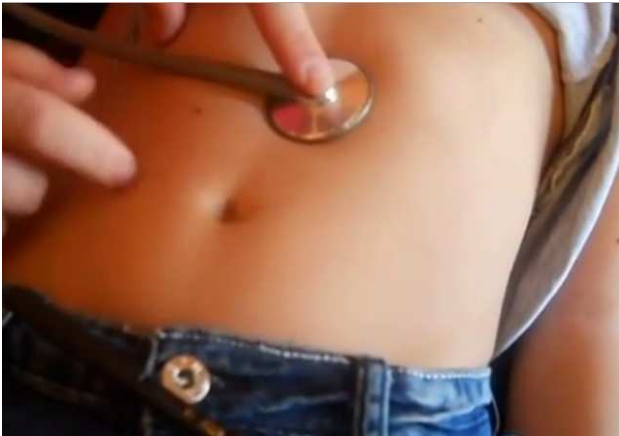How the percussion is done?

The percussions are very light, (with the force you would apply to play with a baby born from 1 week beating the forehead or nose); the finger is held like a hammer; the percussion is done 2 times upon the same point, before moving to the next point (distance between them is about 1 cm), then again do a percussion 2 times upon this point, and so on, moving towards the drum of the stethoscope; without skipping any point; you must maintain a continuity in your percussion: looking at Figure 3a and 3b (and the video above), you must make a percussion on all the points (green dots) of the line (green line) from the more external to the more internal, points very close to the drum. When you reach the first point upon the great curvature of the stomach you can note that the sound is more clear, intense, and hyper-phonetic. The sounds seems to originate near to the ears. Do it for at least 4-5 points, and then connect all them with a marker (see step 4 discussed later).

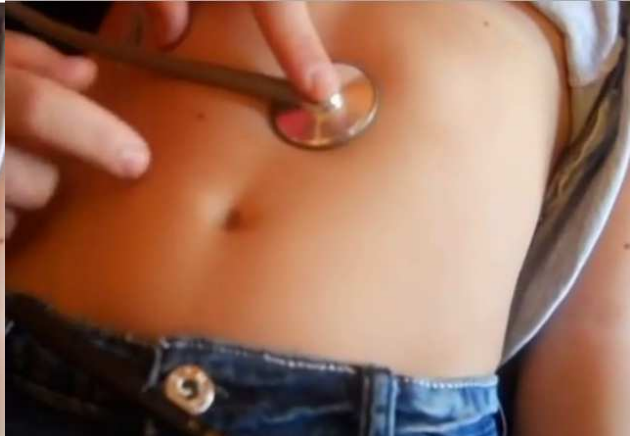Example n. 1 of percussion: watch this video:



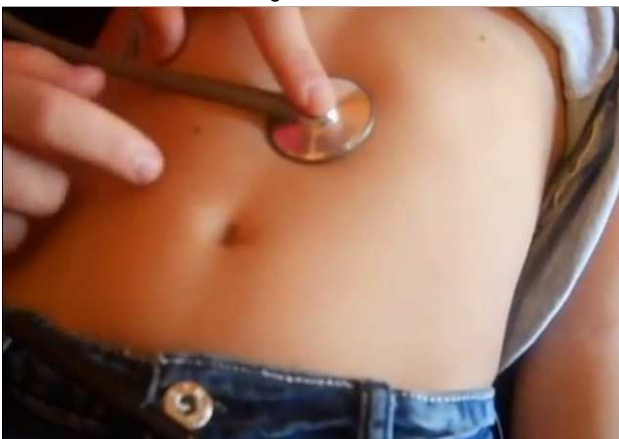<http://www.youtube.com/watch?v=XFdDmoYyZ4I>



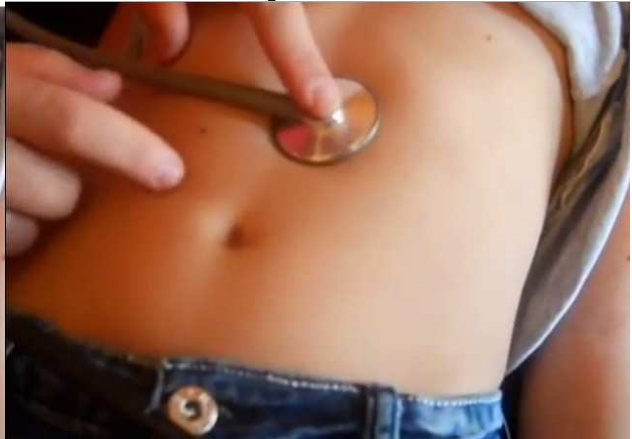*Photogram 3.01*



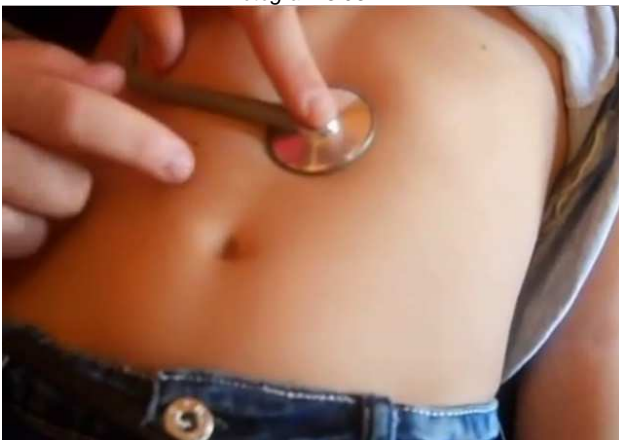*Photogram 3.02*



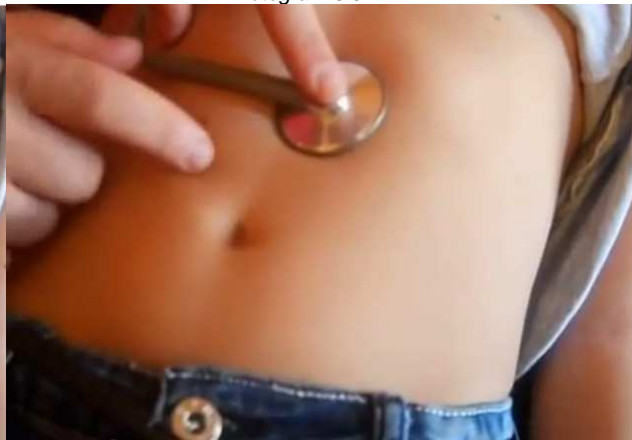*Photogram 3.03*



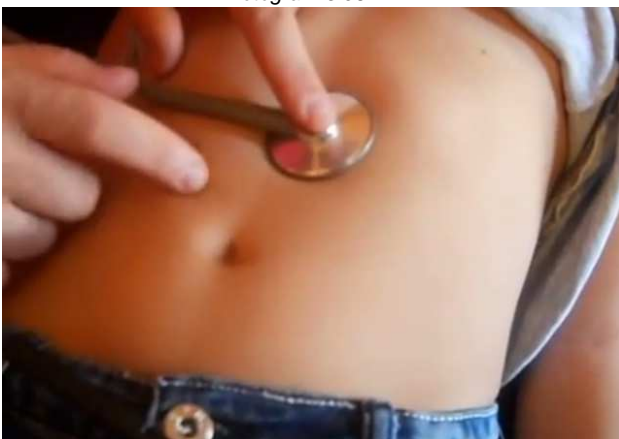*Photogram 3.04*



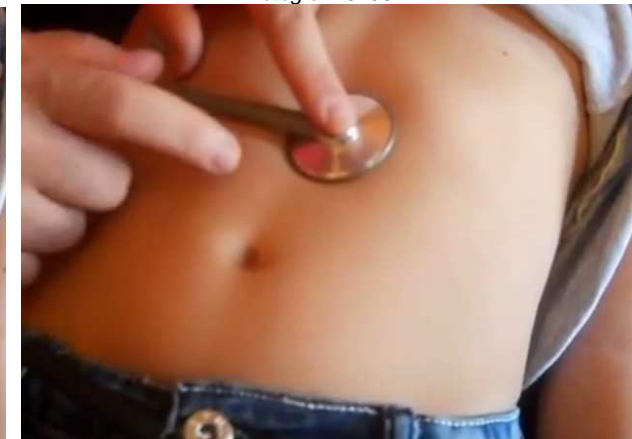*Photogram 3.05*



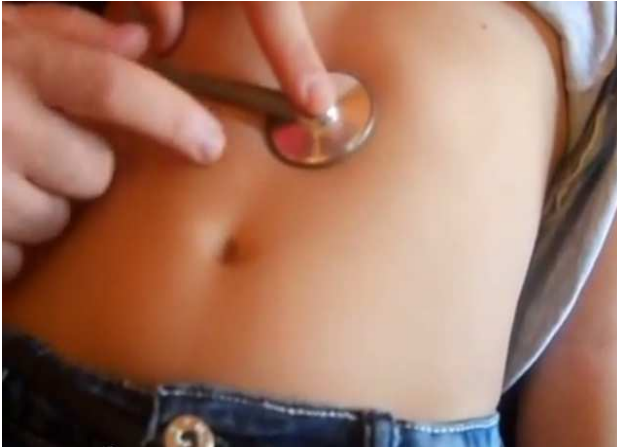*Photogram 3.06*



*Photogram 3.07*



*Photogram 3.08*



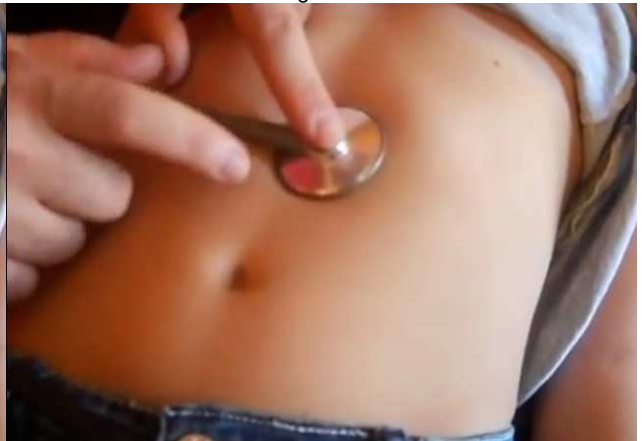*Photogram 3.09*



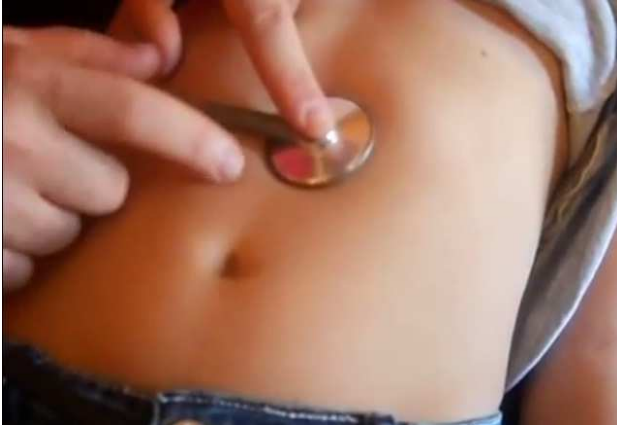*Photogram 3.10*



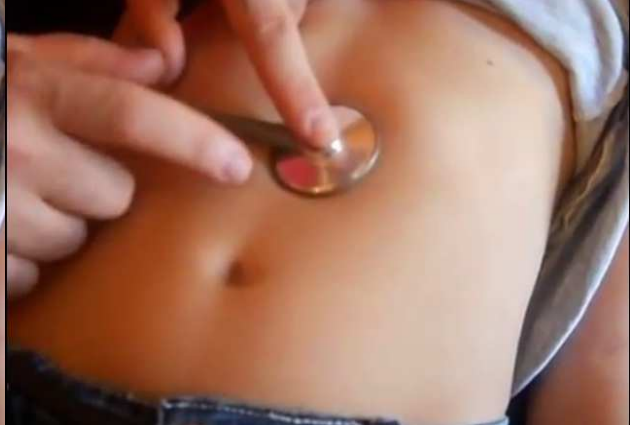*Photogram 3.11*



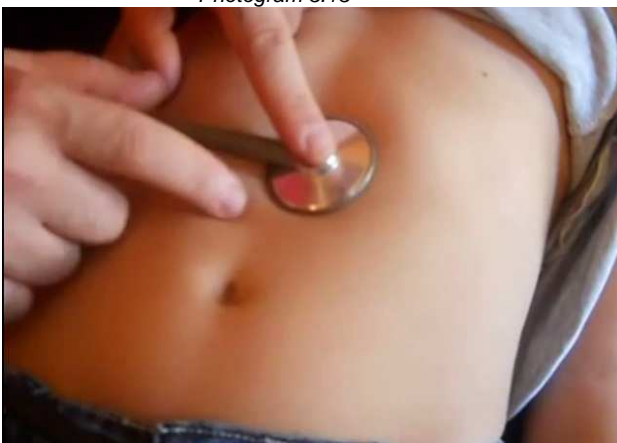*Photogram 3.12*



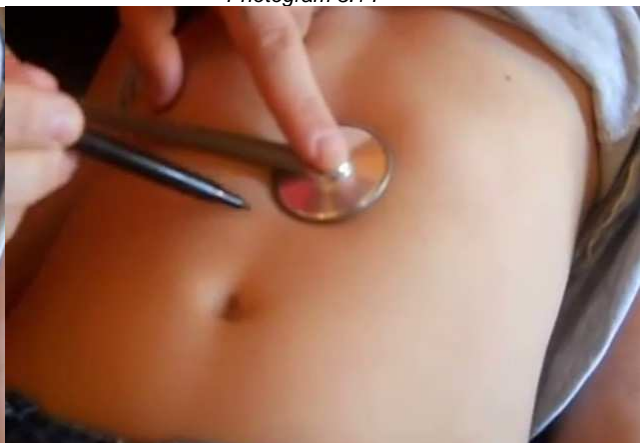*Photogram 3.13*



*Photogram 3.14*



*Photogram 3.15*

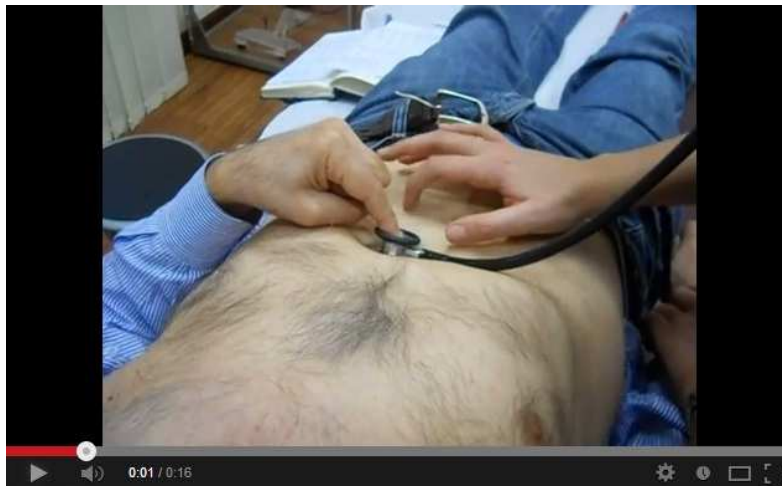

*Photogram 3.16*

**How to do the percussion. Summary.**

The medical doctor performs the percussion with the middle finger, bent like an hammer, directly, smoothly and gently on the skin (radial lines of percussion, green dots in Figure 3, 3b), two times in succession on the same “green dot” before moving to the next one (to not lose the signal) going towards the drum of the stethoscope (green arrows, Figure 3, 3a), along centripetal and centrifugal lines as quickly as possible, always stopping the percussion just before the great curvature of the stomach (green dots, Figure 3, 3b).


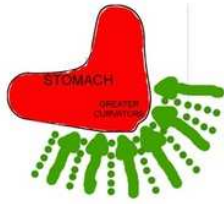
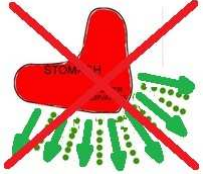
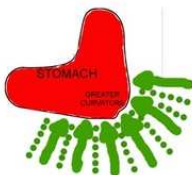
Example n. 2 of percussion. Watch this video:









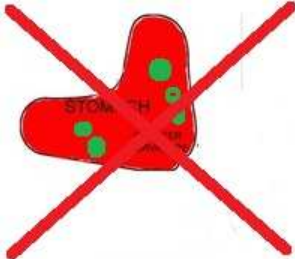
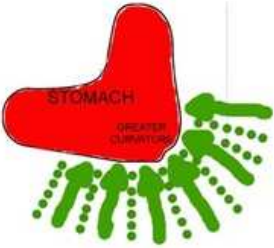


<http://www.youtube.com/watch?v=sXGYbxO29W0>

*Warning! When the percussion is "directly" made on the skin projection of the stomach (or cutaneous projection of any viscera, red area in Figure 3) the sound of percussion is perceived clearly modified, stronger, and seems to "originate near to the ears of the doctor." At this point, it is advisable to carry out the percussion again, for the second time, at least in the early stages, when there is no great experience, in order to avoid some errors, for example, due to a peristaltic wave. The digital percussion must be made only upon the green dots (points of percussion), and never on the projection area of the bowel (the red area - Figure 3 - must never be beaten).*

**Step 3. Common mistakes – wrong behaviors**

Situation	Error – wrong habit - NO	Correct situation - YES
Line of the percussion	 <p>Percussion skipping some dots.. you lose the wave</p>	 <p>Percussion on all the dots' line without skipping any dot</p>
Direction of the percussion	 <p>Percussion from internal to external</p>	 <p>Percussion radial and centripetal from external to internal</p>

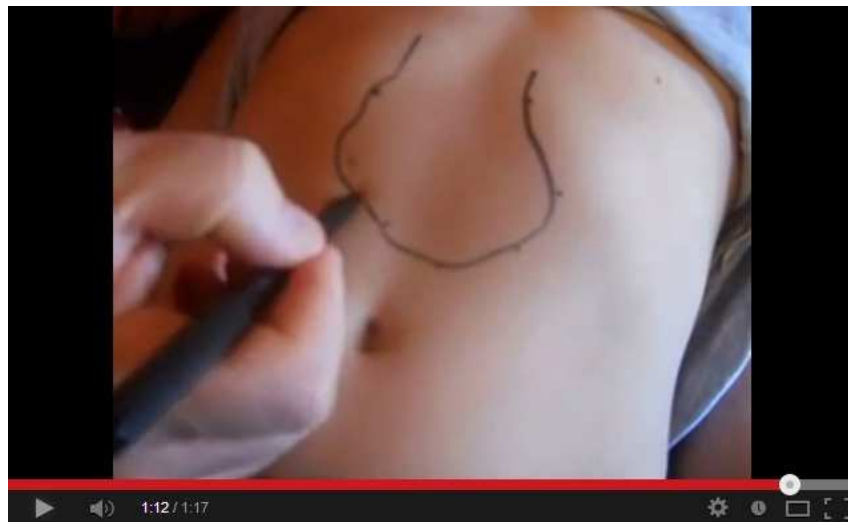
<p>Percussion in every dot</p>	 <p>Percussion one time in every dot</p>	 <p>Percussion two time in every dot</p>
<p>Rapidity of percussion</p>	 <p>Slow percussion is not recommended</p>	 <p>A very quick percussion is recommended</p>
<p>Force of percussion</p>	 <p>Hard percussion is not recommended. Don't press too much</p>	 <p>A very soft, light and gentle percussion is recommended</p>
<p>Finger</p>	 <p>The finger not like a hammer</p>	 <p>The finger is held like a hammer</p>
<p>Place of the percussion</p>	 <p>Don't perform the percussion upon the bowel</p>	 <p>Under the great curvature of the stomach</p>

## Chapter 4.

### Step 4. Delimitation (demarcation) of the stomach

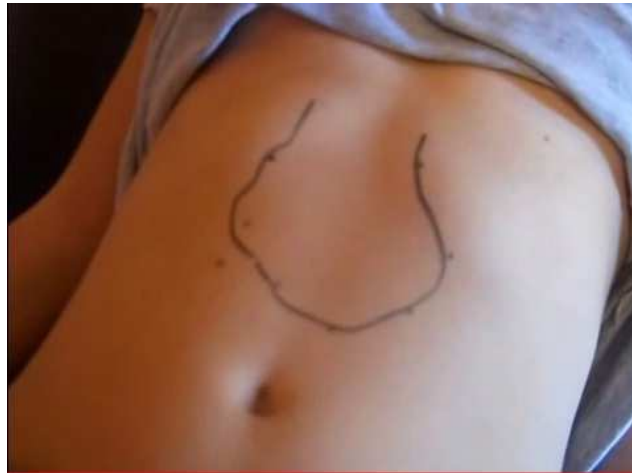

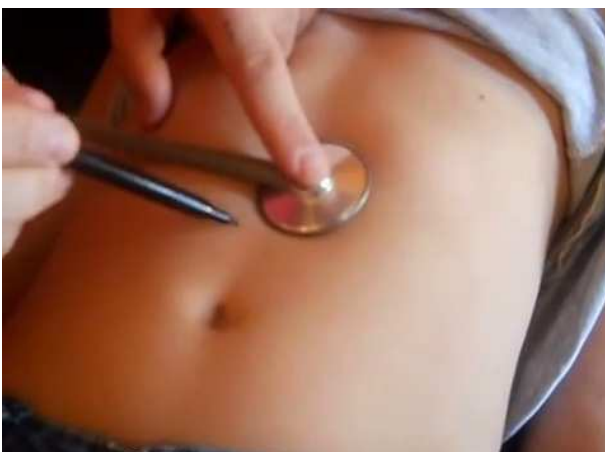Figure 4



Watch the video <http://www.youtube.com/watch?v=Y2MWsbnFfMc> : the demarcation of the stomach is evidences from 16 seconds till the end of this short movie). See also the sequence of photograms 4.01 – 4.14 below.



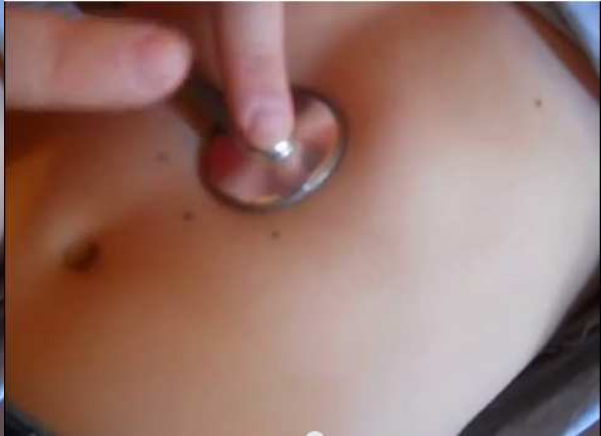Photogram 4.01



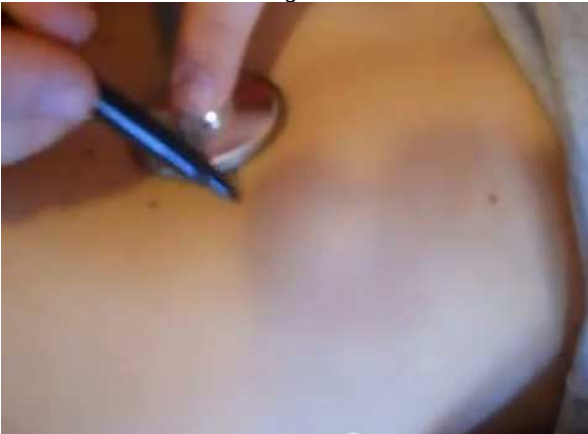Photogram 4.02



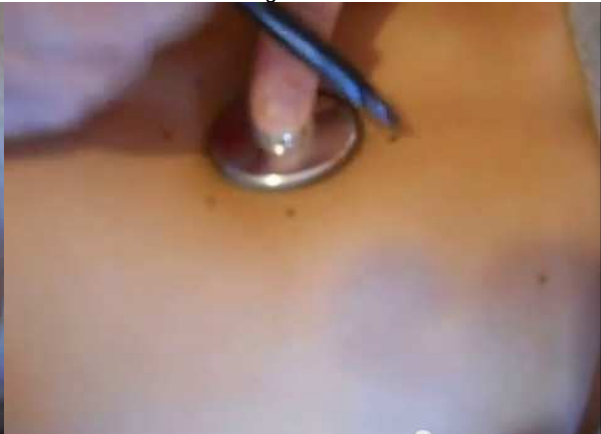Photogram 4.03



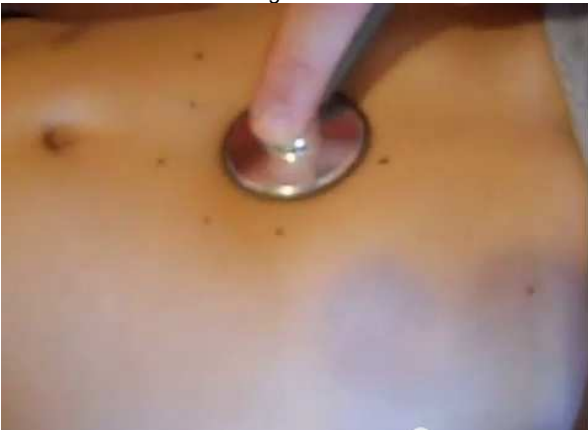Photogram 4.04



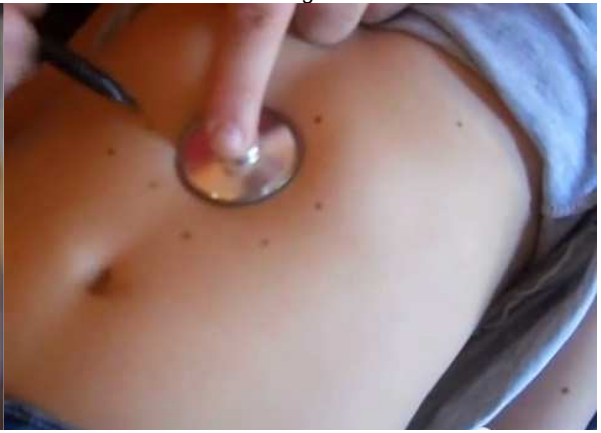Photogram 4.05



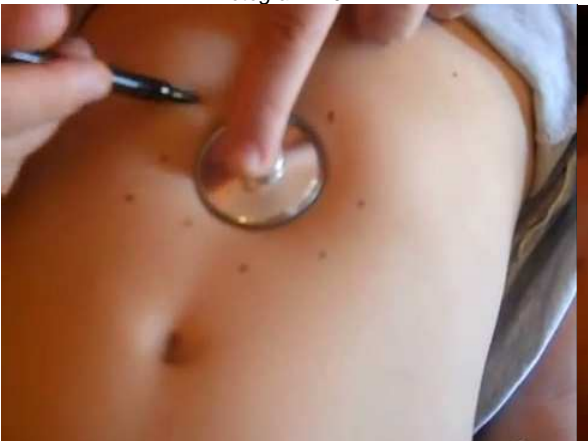Photogram 4.06



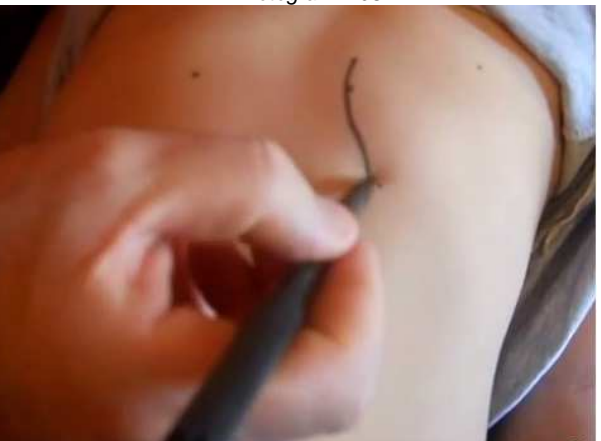Photogram 4.07



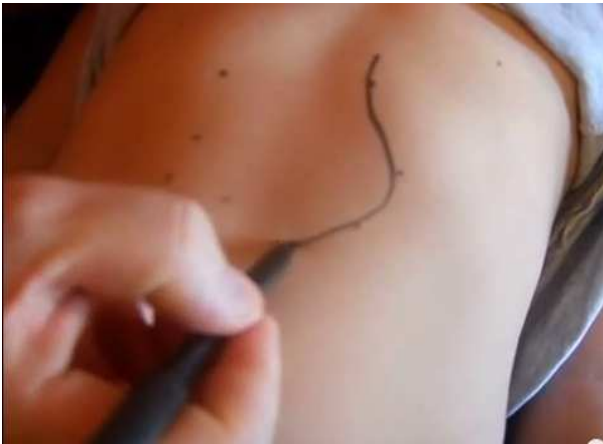Photogram 4.08



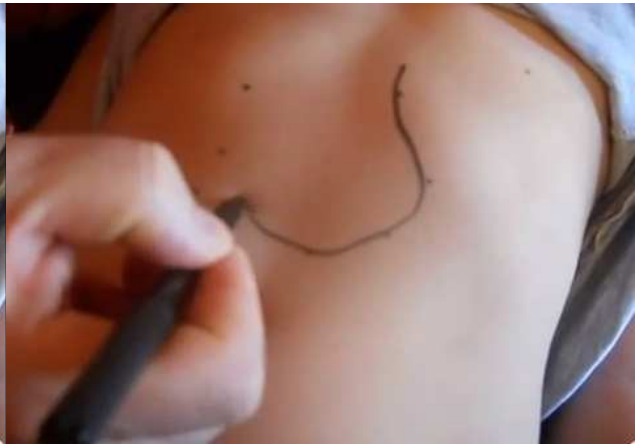Photogram 4.09



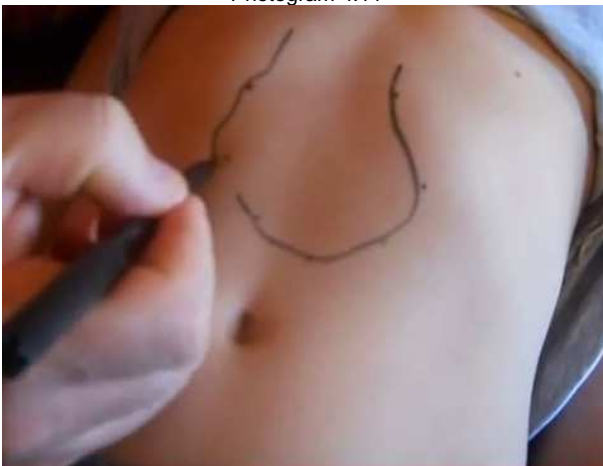
Photogram 4.10



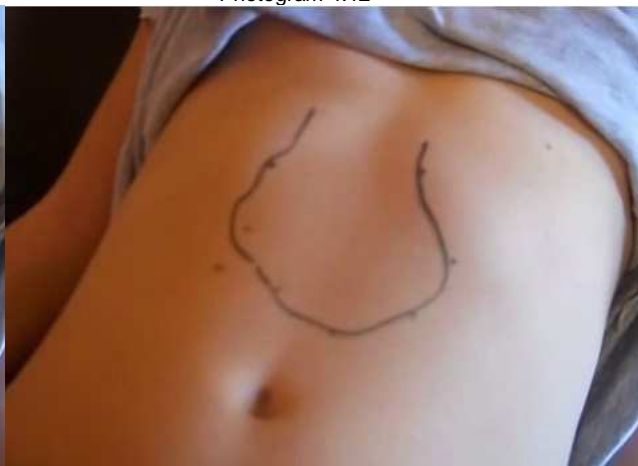Photogram 4.11



Photogram 4.12



Photogram 4.13



Photogram 4.14

From the video <http://www.youtube.com/watch?v=Y2MWsbnFfMc>, in the sequence of Photograms (4.01-4.14) you can see how the demarcation of the stomach is done in practice. At the end of each line's percussion (see Figure 3, 3a, 3b and Photograms 3.1-3.16), you draw with a marker a black dot on the point where the sound changes (Photogram 3.16, Photograms 4.01 - 4.09), and then you connect each black dot with a marker (photogram 4.10 - 4.14): in this way the delimitation of the stomach is done. You can follow this procedure for the delimitation of other organs too (i.e., heart delimitation, ureteral delimitation, spleen demarcation, liver delimitation, etc.). See Figure 4b.

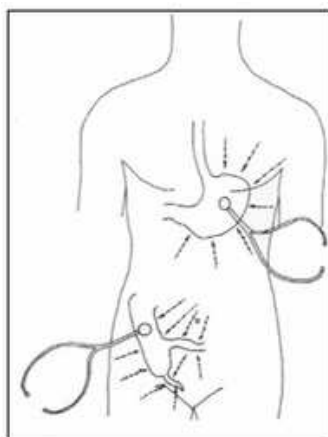


Figure 4b



*Proof of the right delimitation of the stomach: to be sure that the demarcated line corresponds with the border of the stomach, you can do the following maneuver. Invite the patient to breath out with closed glottis (or better, to mimic a straining). You will notice that the sound generated by the percussion on that line (if the boundary line has been done correctly) will be clear and more intense. An useful exercise, at least at the beginning, or in difficult, is to note how the sound changes beating from drum of the stethoscope and going outward, away from the stomach: you will notice that once you have passed the great curve the sound will be fuzzy-away and eaf.*

The steps 1., 2., 3. and 4. are the basic steps for a correct Auscultatory Percussion of the stomach., that is a **static diagnostic**, a static technique useful, like an echography, for some medical purposes, e.g. to assess, after the demarcation of the heart, if there is, or not, a dilated cardiomyopathy.

These steps (1., 2., 3. and 4.) are the basis also for learning and understanding the original diagnostic introduced by Dr. Stagnaro, improving the Auscultatory Percussion of the stomach with new elements, for a **dynamic diagnostics**, useful to explore the non-linear dynamics in biological systems, when and where two or more biological systems are led to communicate each other. This evolution of the Auscultatory Percussion is termed by Stagnaro “Auscultatory Percussion Reflex Diagnostics” (APReD), and we will explore it in detail in the following steps, starting from step n.5.

This is the description of the auscultation that was used in Europe and America until about a century ago. This ‘Auscultatory Percussion’ (**AP**) was used, after abandoning the technique of friction or smearing, which has the defects to be slow, not sensitive, nor highly inaccurate. Now we introduce a new technique that is of Reflex Diagnostics (or **Auscultatory Percussion Reflex Diagnostics – APReD**), which, starting from the base of ‘Auscultatory Percussion’, follows an innovative way in the investigation of the biological realm, following and respecting its complexity and its constant evolution.

## Part II. Auscultatory Percussion Reflex Diagnostics (APReD)

### Chapter 5.

#### Step 5. Percussion in the Auscultatory Percussion Reflex Diagnostics

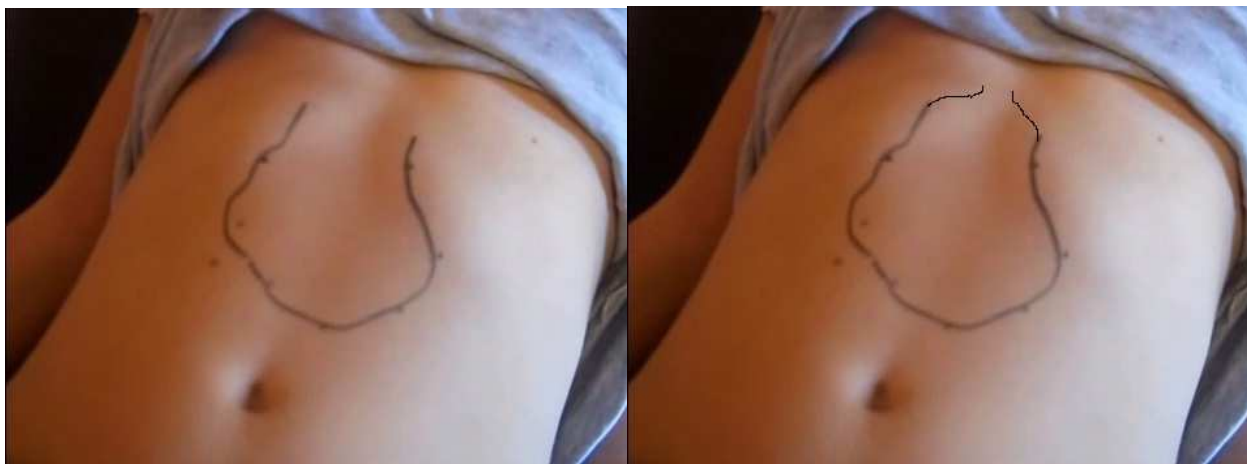

Figure 5. After the first 4 steps, we have marked the stomach borderline.

We highlight at least **two** differences between the Auscultatory Percussion for stomach's demarcation (see step 3 and step 4) and the Auscultatory Percussion in Reflex Diagnostics (the current step 5.) as defined by Stagnaro. The **first difference** is related to **where** exactly the percussion is done.

Auscultatory Percussion for stomach's delimitation is a static diagnosis, so we can start the percussion from very below of the stomach (i.e., from the right iliac crest), because we do not foresee any movement, motility of the stomach, the stomach is at rest (Figure 5a, Figure 5c).

In Auscultatory Percussion Reflex Diagnostics (at this moment we have already finished steps 1. 2. 3. and 4., and the stomach is already delimited with our marker by a black borderline, Figure 5, Figure 5d) we are waiting to some stomach motility (dilation, contraction), so we pay attention to stomach dynamics, and we must be very close to the stomach during our percussion, therefore the Auscultatory Percussion Reflex Diagnostics (APReD) is done very close to the stomach, upon very few points, always following radial and centripetal lines from outward to inward (Figure 5d). The doctor is like a hunter stalking, waiting for his prey movements.

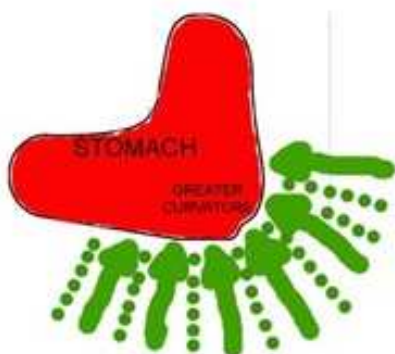


Figure 5a. Auscultatory Percussion for stomach's delimitation




Figure 5b. Auscultatory Percussion for Reflex Diagnostics

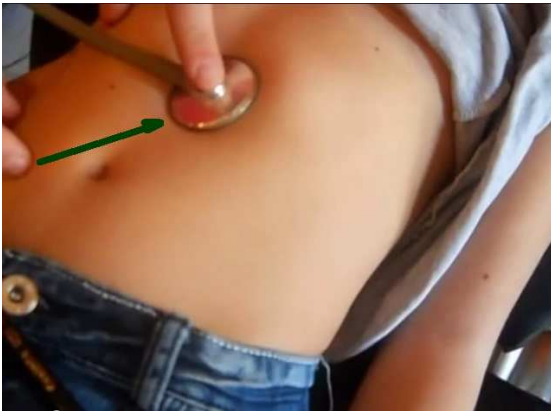

Figure 5c. The percussion starts, for stomach' delimitation, far from the stomach, i.e., from the iliac crest.

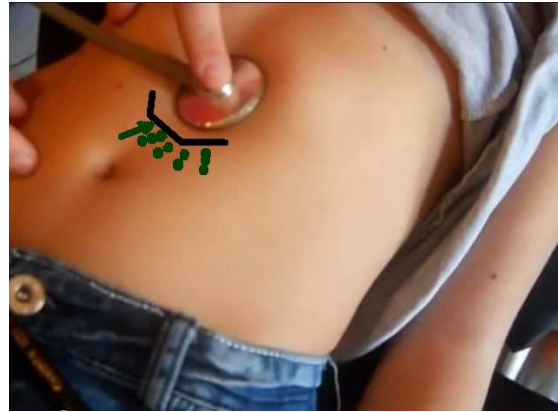
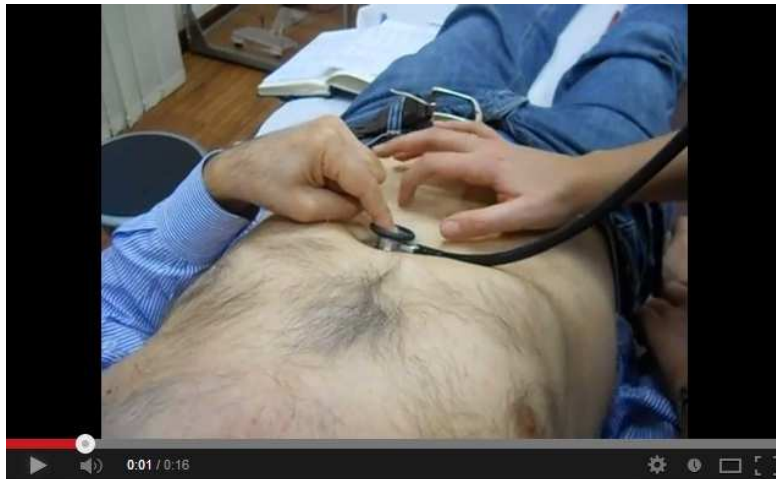
Figure 5d. The stomach is delimited. In Reflex diagnostics the percussion is very close to the stomach's borderline

Have a look at the next video for perceiving the differences between Auscultatory Percussion (AP) for delimitation of the stomach, and Auscultatory Percussion Reflex Diagnostics (APReD).



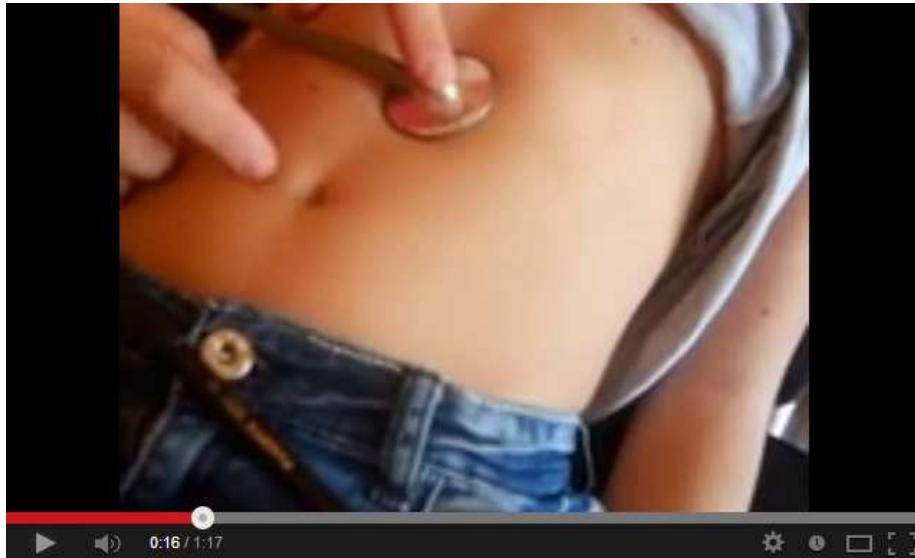Auscultatory Percussion in Reflex Riagnostics. Watch this video:

<http://www.youtube.com/watch?v=sXGYbxO29W0>

The percussion is done very close to stomach borderline, to perceive the stomach's motility.

Note the difference with the Auscultatory Percussion for the demarcation of the stomach, explored in the previous steps: see the video (from 15 sec. to 18 sec. of this short movie):

<http://www.youtube.com/watch?v=Y2MWsbnFfMc>



The **second difference** is related to stomach's delimitation. While in Auscultatory Percussion for stomach demarcation we have seen that we draw the borderline of all the stomach (Figure 5, Figure 5a), and this is an useful didactic exercise for learners, for the purpose of Auscultatory Percussion Reflex Diagnostics (APReD) we need to delimit just a few tract of the great curvature of the stomach (Figure 5b, Figure 5d).

At this moment we have laid the foundations for performing an efficient Auscultatory Percussion Reflex Diagnostics (APReD). On this basis we can go on to the next step (step 6): the stimulation of trigger-points of interest, as follows in details.





About the sounds perceived with the stethoscope, we can catalogue at least 3 different kinds of wave sounds (a,b and c):

**Type a)** it is the sound perceived from the percussion upon the skin projection of the stomach (just in demarcating the big curve) is hyper-phonetic and tympanic. For example, during step 3 for the delimitation of the stomach, when the doctor perceives a change of sound and marks with a black dot this moment, this change id from type b) sound (under the stomach) to type a) sound (borderline of the stomach and stomach itself);

**Type b)** it is the sound perceived from the percussion below the great curvature of the stomach (i.e., when we demarcate the big curve and strike along concentric and radial lines) is hypo-phonetic, muffled and "far away";

**Type c)** it is the sound that we perceive on the stethoscope immediately below the great curvature of the stomach once the expansion (dilation of the stomach) appears. This sound is clearly, distinctly hyper-phonetic and tympanic in an area in which, at rest, the sound was muffled distant and hypo-phonetic (sound type b at rest).

**Step 5. Common mistakes – wrong behaviors**

Situation	Error – wrong habit - NO	Correct situation - YES
Where the percussion starts	 <p>Percussion starts from the iliac crest (like in step 3) ..too far from stomach's border</p>	 <p>Percussion starts and done very close to the stomach's border</p>
Place of the percussion	 <p>Percussion under all the great curvature of the stomach</p>	 <p>Percussion under just one part of the great curvature of the stomach</p>

## Chapter 6.

### Step 6. Stimulation of the trigger-points of interest

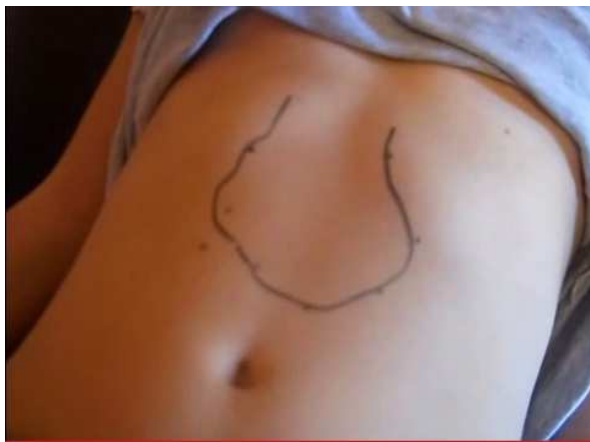

Figure 6a

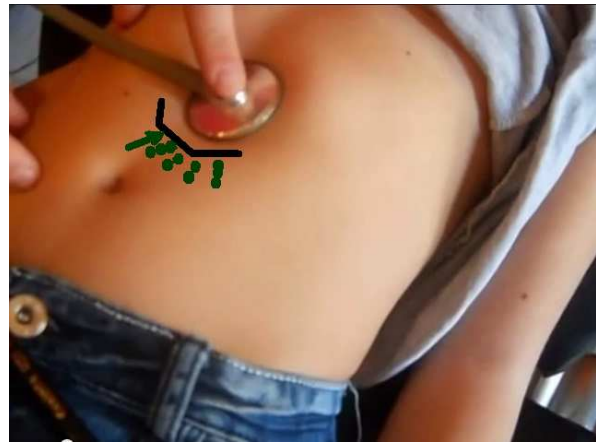
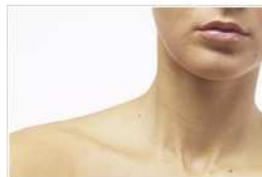
Figure 6b

We are now doing an Auscultatory Percussion very close to the borderline of the great curvature of the stomach (Figure 6b), as explored in step 5, so we are creating a wave, but we do not yet inform this wave where to go, in what direction. Our purpose is to create a communication feedback between the stomach and the parenchyma we want to explore for our diagnosis, for instance heart's parenchyma (see an overview of different trigger points of interest, i.e., diabetic trigger-points, cardiac trigger points, osteoporotic trigger-points, etc., in <http://www.sisbq.org/le-costituzioni-sbq.html> ) [25].

**Reale Rischio Congenito di patologia gastrointestinale**  
(Segno di Stagnaro)

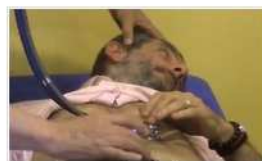

Appena sopra il giugulo, lungo la linea mediale del collo. Pressione digitale

Lt = 0 ----> simultaneo

Lt = 16

**Terreno Oncologico**  
(Segno di Rinaldi)  
GUARDA IL VIDEO

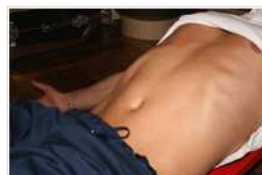

Proiezione cutanea dell'epifisi o del GH - SRH. Pressione digitale

Lt = 0 ----> simultaneo

Lt = 16

**Reale Rischio di nefropatia**  
(Segno di Pollio)



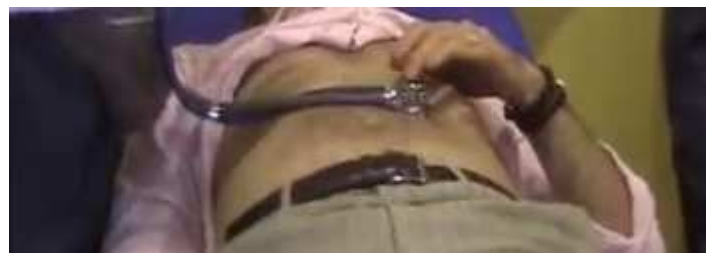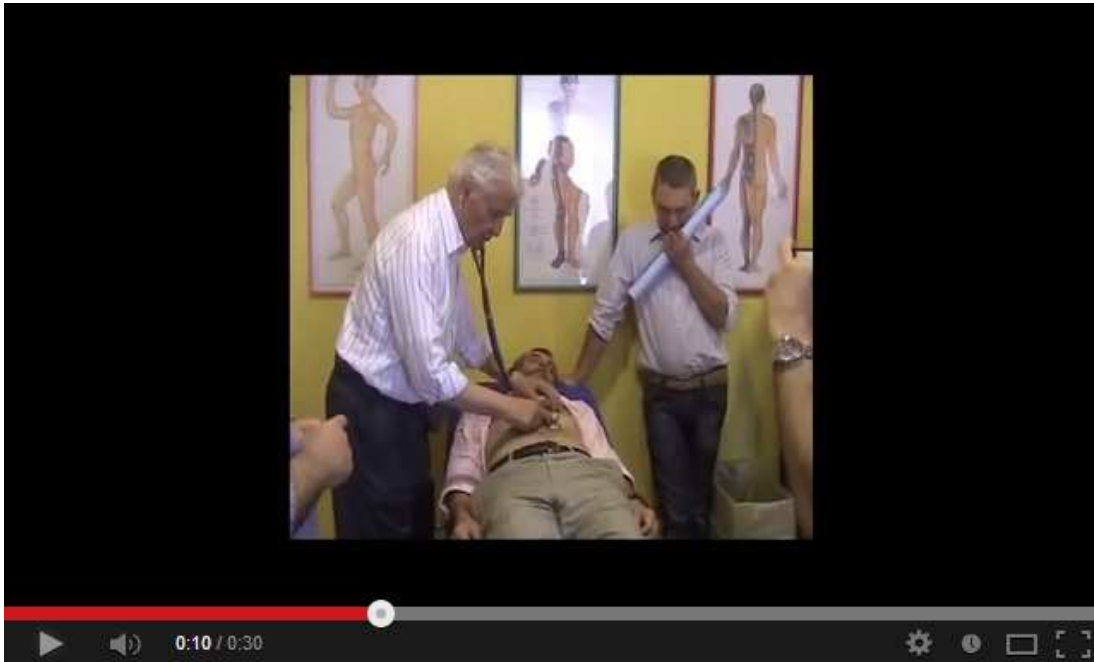Regione latero-addominale. Proiezione cutanea di un rene. Pizzicotto cutaneo

Lt = 0 ----> simultaneo

Lt = 16

If we are interested in a cardiovascular diagnosis, we have to stimulate the cardiac trigger-points, i.e., any point of the precordium (skin projection area of the heart). So, summing up:

I) we have a patient psycho-physically relaxed, with open eyes, helping the doctor by keeping the drum of the stethoscope adherent to the skin (Figure 6c); [http://www.youtube.com/watch?v=ne\\_RM\\_u4KnM](http://www.youtube.com/watch?v=ne_RM_u4KnM)



*Figure 6c*

II) the doctor, with one hand, performs the Auscultatory Percussion close to the borderline of the great curvature of the stomach, as explained before (Figure 6b, 6d) <http://www.youtube.com/watch?v=XFdDmoYyZ4I>;



*Figure 6d*



III) continuing and without stopping the percussion, the medical doctor with the other hand stimulates any point of the precordium with a digital pressure, in order to evoke a cardio-gastric reflex (Figure 6e, 6f).

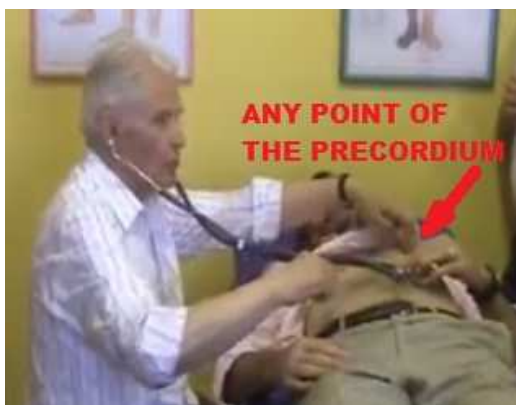
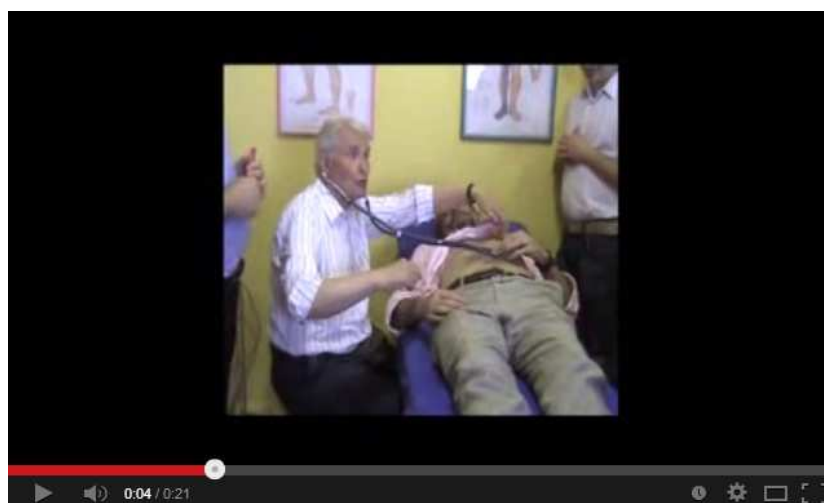
Figure 6e



Figure 6f

Have a look at the following video where I), II) and III) are resumed:  
[http://www.youtube.com/watch?v=77\\_4PUlxnwU](http://www.youtube.com/watch?v=77_4PUlxnwU) .





## Chapter 7.

### Step 7. Trigger points: magnitude (intensity) of the stimulation

When the medical doctor stimulates with a fingertip the trigger points of interest, i.e., any point of the precordium with a digital pressure (Figure 7a), the physician is informing the wave, created by the percussion, where to go, i.e., to go toward a well defined direction. Stimulating the precordium we are creating a communication feedback between stomach and heart: the wave moves from the stomach to heart's parenchyma, then the wave refracts and comes back to the stomach. Therefore the physician is stalking, with the percussion, close to the great curvature of the stomach, to verify IF, WHEN, FOR HOW LONG and HOW MUCH the stomach dilates (and IF there is any tonic gastric contraction), all interesting qualitative parameters of stomach motility, as consequence of the interaction stomach-heart so far induced.

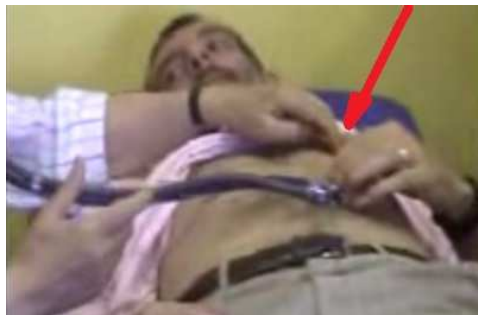

Figure 7a

In Auscultatory Percussion Reflex Diagnostics there are different “magnitudes” of the stimulus. We can identify at least 5 magnitudes: slight, slight (mild) - moderate, mean (average), mean (medium) - intense, intense. For example, if we chose an interval of reference [0,1], we can assign to each magnitude a value between 0 and 1, i.e., slight = 0.1; slight moderate = 0.3; mean = 0.5; mean intense = 0.8; intense = 1.

Higher is the magnitude of the stimulus, lower is the information we obtain through the Auscultatory Percussion Reflex Diagnostics, because as higher is the stimulus, lower is the flow of energy-matter-information flowing in the interacting bio-systems.

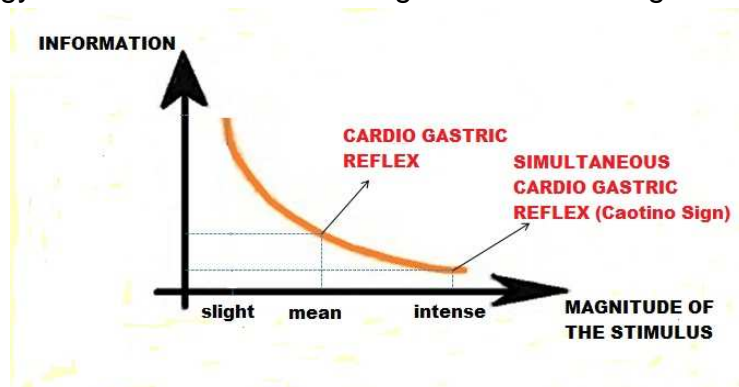


Figure 7b

In Figure 7b you can note that the information we get with an intense stimulus is very low, because with an intense pressure we are obstructing the flow of energy-matter-information (blood flow). This is the case of the cardio gastric reflex with simultaneous stomach's dilation (in pathology or Inherited Real Risk of cardiovascular disease) we are going to explore in the next step (see step 8).

## Chapter 8.

### Step 8. Intense stimulation of trigger points: the simultaneous reflexes

What do we mean for “intense” stimulation? To have an idea, we refer to the same hard force we would use to calm an hemorrhage.

In intense stimulation of the trigger points of interest, i.e., intense pressure upon any point of the precordium, we are obstructing the flow of energy-matter-information (blood flow), so that the communication feedback between stomach and the heart’s parenchyma seems to be broken or interrupted. In the classical knowledge of bio-systems dynamics in space-time, we would not expect any stomach motility, because we are completely obstructing the communication feedback between stomach and heart.

But this hypothesis is not true, because we can observe in some cases the stomach motility, and when the stomach dilates, this happens **simultaneously** with the intense stimulus of the precordium. This is due to a phenomenon well known from the physics, termed ‘quantum entanglement’. By mean of the Auscultatory Percussion Reflex Diagnostics (APReD) and intense pressure on trigger points of interest we observe phenomena of bio-quantum entanglement.

There is stomach’s motility just in case of overt diseases, i.e., cardiovascular pathologies, or in case of Inherited Real Risk of Coronary Disease (90% of subjects at risk), or risk of other cardiovascular diseases such as Valvular heart disease, septal patency IA and IV, Taka Tsubo syndrome, arrhythmogenic right Ventricleopathy, etc.. (10% of subjects at risk). In case of healthy subjects (clinically healthy and without any risk of cardiovascular disease) there is not any stomach motility (the stomach just dilates after 16 seconds from the moment of the intense stimulus upon the precordium, because we induced a physiological tissue acidosis). This is called (negative) Caotino Sign.

Have a look at the following video in which the Caotino Sign is showed:

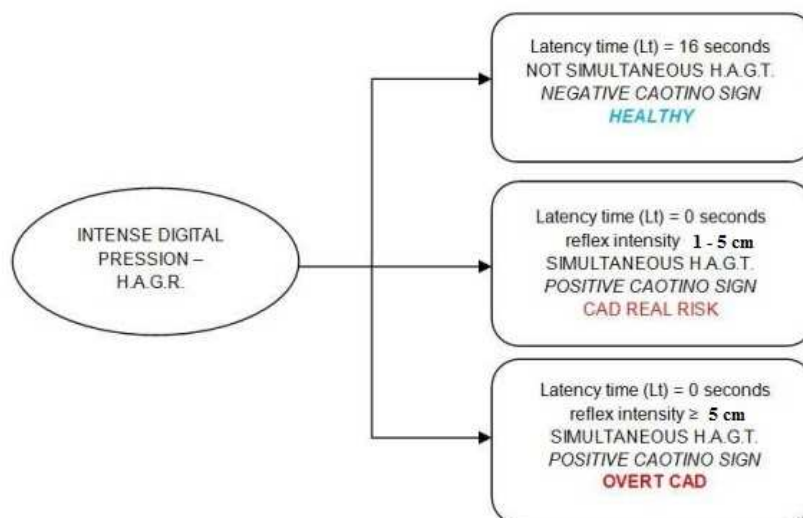


<http://www.youtube.com/watch?v=eGQVJuLf0Ko> .

To see how the stomach moves, how it dilates, how is the stomach motility like, double click on the following animation:



[http://www.sisbq.org/provetecniche\\_08.html](http://www.sisbq.org/provetecniche_08.html) .



Legend. H.A.R.G. (Heart Aspecific Gastric Reflex); CAD (Coronary Artery Disease); Lt (Latency time)  
Figure 8a

Figure 8a shows the different options available under intense digital pressure upon any point of the precordium, so evoking a heart aspecific gastric reflex. **The parameters of interest** for the diagnosis are: **a) the latency time of the reflex (in sec.)** (the seconds spending from the moment in which the doctor presses with a finger upon the precordium, till the moment in which the stomach dilates).

There are just 2 options: simultaneous reflex or 0 seconds latency time; 16 seconds latency time in case of healthy subjects not at risk of any cardiovascular disease). In the flow chart (Figure 8a) you can note that the simultaneous reflex can occur both in case of overt CAD (Coronary Artery Disease) and in case of Inherited Real Risk of CAD. To distinguish between the latter 2 cases the physician can consider a second parameter of interest, that is **b) the intensity of the reflex (in cm)**. The intensity of the reflex refers to how many cm the stomach expands.

In Figure 8b a stomach at rest is drawn. In Figure 8c is drawn the same stomach simultaneously dilated under intense stimulation upon any point of the precordium. The intensity of the reflex refers to the cms of dilation.



Figure 8b



Figure 8c

If the dilatation is less than 1 cm, than there is just an Inherited Real Risk of cardiovascular disease, else (dilatation  $\geq 1$ cm) there is an over pathology.

In order to explore the severity of the pathology, or of its Inherited Real Risk (and also its exact location), the physicians must perform a more refined diagnosis, with the same technique but with a stimulus of mean magnitude on the precordium, thus allowing a sufficient amount of matter-energy-information flow (blood flow), and more diagnostic information (Figure 7b), including those offered by nonlinear dynamics systems typical of dissipative systems far from equilibrium. This diagnosis and its parametric information will be explored in next step (step 9).

About the wave sound perceived by the ear during the Auscultatory Percussion we can distinguish 2 kinds of sound (type b and type c), while type a (see step 5) must not be heard (percussion upon the stomach's projection area is forbidden):

**Type b)** the perceived sound by the percussion below the great curvature of the stomach (the sound perceived by the physician when he is striking immediately under the great curvature of the stomach, with stomach at rest, not yet dilated); characteristic of this sound: the sound is hypo-phonetic, muffled and "far away";

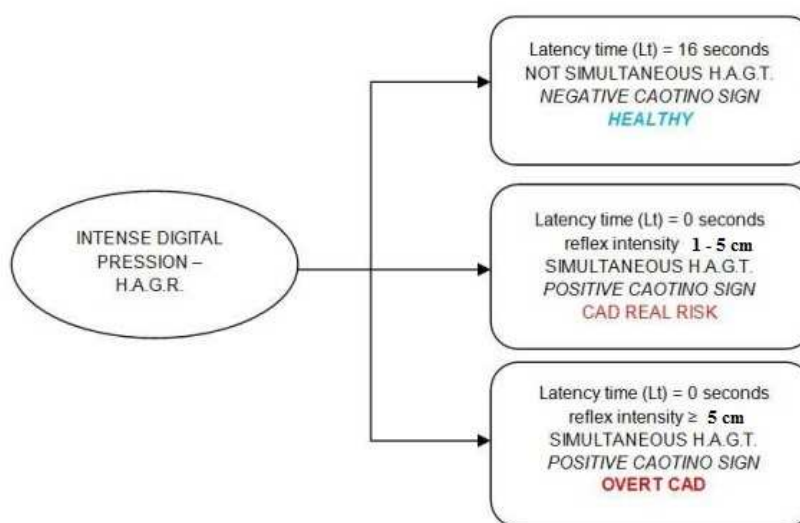
**Type c)** the sound perceived by the physician on the stethoscope during his percussion, immediately below the greater curvature of the stomach once the expansion (dilation of the stomach) appears. The sound is clearly, distinctly hyperphonetic and tympanic in an area in which, at rest, the sound was muffled and distant hypophonetic (sound type b at rest).

## Chapter 9.

### 9. Mean stimulation of trigger points: the cardio gastric reflex

As seen in step 8, in case of intense pressure on precordium, **Caotino's sign**, we considered the following 2 parameters, Latency time (Lt) and Intensity (I):

- a) **Latency time (Lt):** the seconds elapsing from the moment of the stimulus digital pressure upon the skin projection of the precordium) to the moment in which the stomach dilates; in this case we have just 2 options:
  - a.1) *reflex simultaneous* to the precordium if the **intense stimulus** (latency time = 0 seconds), in subjects at risk of Coronary Heart Disease or with cardiopathy in progress (*positive Caotino's sign*), either
  - a.2) *physiological reflex* (latency time = 16 seconds) in healthy subjects (*negative Caotino's sign*).
- b) **Intensity (I):** the dilatation of the stomach in cms depends on the severity of the disease; less or more than 1 cm).



Legend. H.A.R.G. (Heart Aspecific Gastric Reflex); CAD (Coronary Artery Disease); Lt (Latency time)

Figure 9a

Have a look here: [http://www.sisbq.org/provetecniche\\_08.html](http://www.sisbq.org/provetecniche_08.html)

In case of *positive Caotino's sign* (Figure 9a), to make the differential diagnosis, the physician applies a mean-intense digital pressure with a fingertip on different points of the precordium (**Gentile's sign**) [26-37].

In this induced situation, we can get more informative parameters than those obtained with the previous sign, i.e., through Caotino's sign.

In case of mean pressure on precordium (**Gentile's sign**) we consider the following parameters about the heart gastric reflex (the magnitude of the pressure, i.e., **mean**

**(average) stimulus** can be objectively quantitatively defined, i.e., in term of quantified pressure dine/square-cm):

- 1) **Latency time (Lt)**: the seconds lasting from the moment of the stimulus (mean digital pressure upon the skin projection of the precordium) to the moment in which the stomach dilates;  
*The Latency time of the reflex is related to tissue oxygenation, and tissue pH;*
- 2) **Duration (D)**: the seconds elapsing from the moment of the dilation to the moment in which the stomach comes back to the basal position at rest;  
*The Duration of the reflex is related to the Microcirculatory Functional Reserve and to the fractal dimension (see Appendix A);*
- 3) **Intensity (I)**: the cms of greater\* dilation of the stomach ( depending on the severity of the disease; less or more than 2 cm);  
*The Intensity of the reflex is related to the seriousness of the underlying disorder;*
- 4) **differential latency time (dlt)**: the seconds passing from the moment in which the first reflex disappears (the stomach after the dilation comes back to its basal position at rest) to the beginning of the second reflex. The timer (seconds counting) starts from the exact moment in which the stomach comes back to the basal position at rest, and it stops in the exact moment in which the stomach starts his second dilatation.  
*The differential latency time parallels and it is consistent with the latency time after preconditioning.*

We analyze now in detail each of the above mentioned parameters: Latency time (Lt), Duration (D), Intensity (I), differential latency time (dlt).

## 9.1 Latency time of the cardio gastric aspecific reflex in Gentile's sign

The **Latency time (Lt)** of the cardio-gastric reflex in case of mean digital pressure on any point of the precordium is the period of time, in seconds, counted as follows.

Latency time (Lt) are the seconds lasting from the moment of the stimulus (mean digital pressure upon the skin projection of the precordium) to the moment in which the stomach dilates.

In summary, in practice we proceed as follows. We put in action the 'step 1' (position of the patient), the 'step 2' (position of the stethoscope), the 'step 3' (auscultatory percussion of the stomach for its delimitation), the 'step 4' (delimitation of the stomach). After doing, the delimitation (demarcation) of the stomach, we proceed as learned in the 'step 5' (auscultatory percussion for reflex diagnostics), but considering now the stimulation of the trigger-points, i.e., any point of the precordium ('step 6'), we make a change with respect to 'step 8' (intense stimulation): the magnitude of the stimuli ('step 7') is now mean (average) (the current 'step 9') and not anymore intense, as done for Caotino sign ('step 8').




		
<b>1. Demarcation of the stomach (step 1,2,3,4)</b>	<b>2. Auscultatory percussion for reflex diagnostics (step 5)</b>	<b>3. Mean (average) stimuli on any point of the precordium (step 9)</b>

Figure 9b. Procedure to evoke the cardio-gastric reflex with mean stimulation on any point of the precordium.

The physician begins the Auscultatory Percussion (as in 'step 5') and without stopping the percussion presses with a finger pulp upon any point of the precordium with a mean (average) force of the stimuli ('step 9'), continuing the Auscultatory Percussion. From the moment in time in which the doctor makes the digital pressure on any point of the precordium (Figure 9b, 'step 9'), (always continuing the percussion, always continuing to press with the finger pulp), he starts to count the seconds, the time spending: 1 sec., 2 sec., 3 sec., 4 sec., 5 sec.,... before the stomach dilatation. In healthy subjects, in the moment we count '**8 seconds**', the stomach dilates: this is the Latency time of cardio-gastric aspecific reflex with mean stimulation on any point of the precordium (Figure 9c; Figure 9d).

#### How to measure the Latency time of the cardio-gastric aspecific reflex in Gentile's sign




		
<b>1. Mean (average) stimuli on any point of the precordium (step 9)</b>	<b>2. The Stomach is not yet moving, and it stays in this position for some seconds</b>	<b>3. The stomach begins the dilatation</b>
<b>Moment to start the timer! 0 sec.</b>	<b>The timer is counting: 1,2,3,4,5,..</b>	<b>The timer stops: in health it stops at 8 sec.</b>

Figure 9c. Crucial moments for time counting of Latency time: 1. The moment of the stimuli (start-up of Latency time) and 3. The moment when the stomach starts to move (end of Latency time).

# THE GASTRIC ASPECIFIC REFLEX

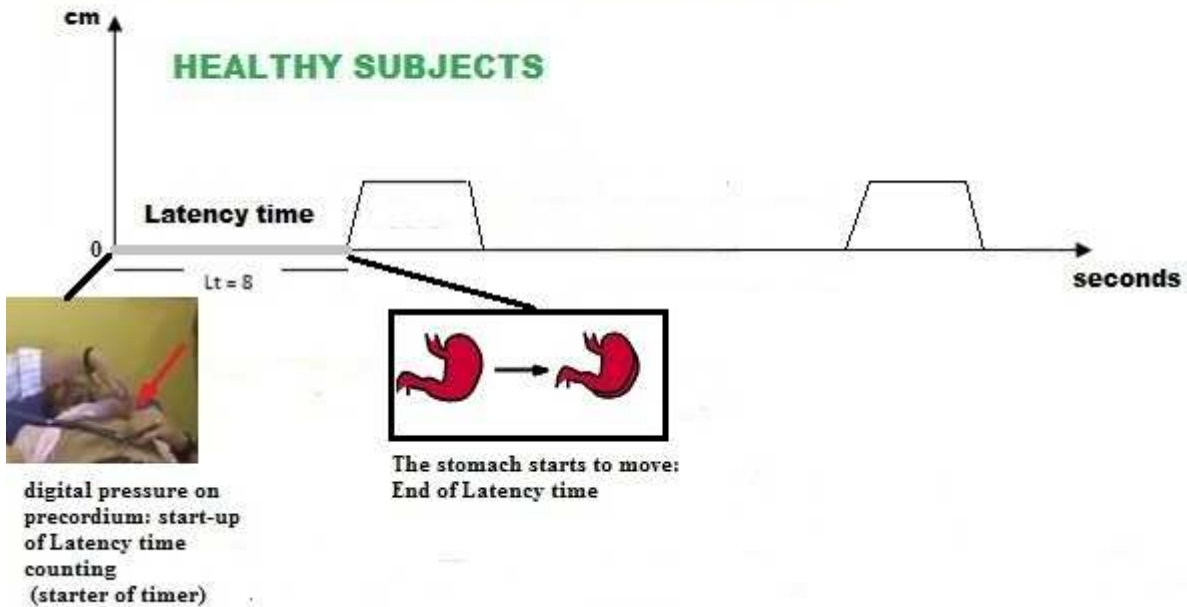


Figure 9d. 'Lt counting' starts-up with the digital pressure on precordium and it finishes as the stomach begins to move.

In Table 1 the Latency time of the cardio gastric aspecific reflex for healthy subjects, subjects with Inherited Real Risk of Coronary Artery Disease (CAD) and subjects with different severity of the cardiovascular pathology are resumed.

## Lt of Cardio-Gastric Aspecific Reflex with mean digital pressure on any point of the precordium

<i>Examined Subjects</i>	<i>Latency time (Lt) in seconds</i>
<i>Healthy subject</i>	<i>Lt = 8</i>
<i>Inherited Real Risk of CAD (pre-clinical stages)</i>	<i>Lt = 8</i>
<i>Pathology (early clinical stages)</i>	<i>7 &lt; Lt ≤ 8 sec.</i>
<i>Pathology (in evolution)</i>	<i>6 ≤ Lt ≤ 7 sec.</i>
<i>Pathology (advanced stages)</i>	<i>Lt &lt; 6 sec.</i>

Table 1. Legend: Lt = Latency time of the reflex in seconds.

In case of healthy subjects (Table 1) the Latency time is 8 seconds, while in case of pathology is less than 8 seconds. In comparison with "healthy" parameters (Figure 9e, diagram above), **the latency time (Lt) tends to diminish** (Figure 9e, diagram below) only from the early stages of the pathology, even silent and asymptomatic ( $7 \leq Lt \leq 8$ ) and it diminishes more and more with decreasing Lt (Pathology in evolution:  $6 \leq Lt \leq 7$ ); (advanced stages of pathology:  $Lt < 6$ ) depending on the severity of the disease.



## THE GASTRIC ASPECIFIC REFLEX

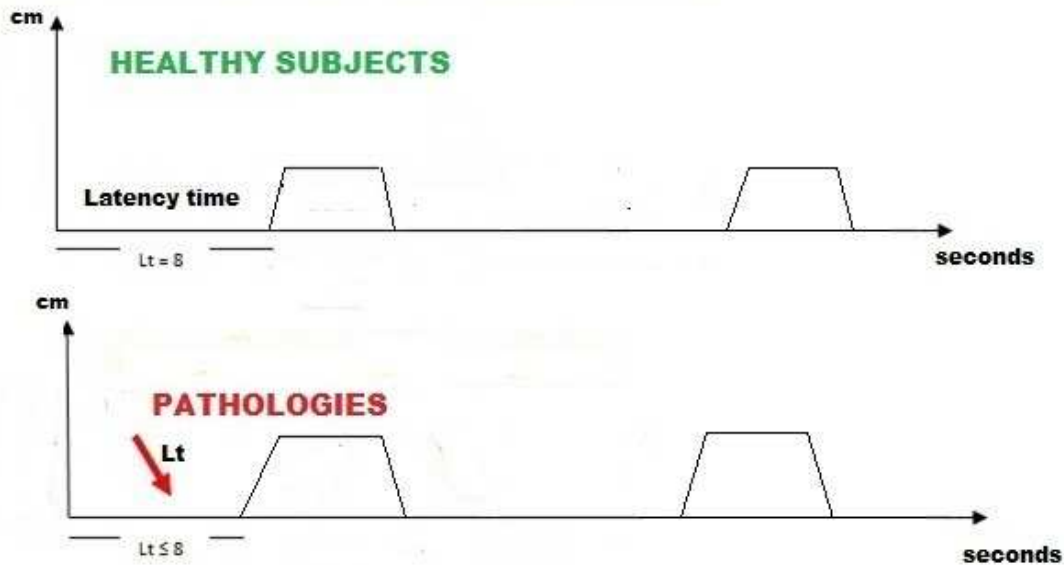


Figure 9e. Latency time ( $Lt$ ) is 8 seconds in healthy subjects, while it diminishes ( $Lt \leq 8$ ) in subjects with pathologies.

You can note in Table 1 that the Latency time of healthy subjects and the Latency time of subjects with Inherited Real Risk of CAD is the same (8 seconds). How can we differentiate and distinguish them? You can do it looking at the other parameters (duration of the reflex, intensity of the reflex, differential latency time of the reflex) that we will analyze later (see 9.2, 9.3 and 9.4), but also performing the so called maneuver of 'preconditioning'. 'Preconditioning' means to repeat the Auscultatory Percussion Reflex Diagnostics (APReD) as just explained (Figure 9b) after exactly a pause of 5 seconds from its end, i.e., the physician should repeat the diagnosis of cardio-gastric reflex with mean digital pressure on precordium, after a pause of exactly 5 seconds from the end of the first one. In case of healthy subjects the Latency time after preconditioning is doubled ( **$Lt = 16$  seconds**), while in case of Inherited Real Risk of CAD the Latency time (Table 2, second column) is less than doubled ( **$Lt < 16$  seconds**). In case of pathology, depending on its severity we have a decreasing latency time after preconditioning (Pathology in evolution:  **$12 < Lt < 16$** ); (advanced stages of Pathology:  **$Lt < 12$** ).

**Latency time of Cardio-Gastric Aspecific Reflex after preconditioning**

	<i>Latency time (<math>Lt</math>)</i>	<i>Latency time (<math>Lt</math>) after preconditioning (pause of 5 sec.)</i>
<i>Healthy subject</i>	<i><math>Lt = 8</math></i>	<i><math>Lt = 16</math></i>
<i>Inherited Real Risk of CAD (pre-clinical stages)</i>	<i><math>Lt = 8</math></i>	<i><math>Lt &lt; 16</math></i>
<i>Pathology (early clinical stages)</i>	<i><math>7 &lt; Lt \leq 8</math> sec.</i>	<i><math>Lt &lt; 16</math></i>
<i>Pathology (in evolution)</i>	<i><math>6 \leq Lt \leq 7</math> sec.</i>	<i><math>12 &lt; Lt &lt; 16</math></i>
<i>Pathology (advanced stages)</i>	<i><math>Lt &lt; 6</math> sec.</i>	<i><math>Lt &lt; 12</math></i>

**Table 2.** Legend:  $Lt$  = Latency time of the reflex in seconds.

## 9.2 Duration of the cardio gastric aspecific reflex in Gentile's sign

The **Duration (D)** of the cardio gastric reflex represents the time in seconds elapsing from the moment of the dilatation of the stomach to the moment in which the stomach comes back to the basal position at rest (Figure 9f, Figure 9g).

### How to measure the Duration of the cardio-gastric aspecific reflex in Gentile's sign




		
1. <b>The stomach begins</b> the dilatation, it starts to move	2. <b>The stomach is moving</b> , it reaches its maximal dilatation, and then it is returning	3. <b>The stomach is returned</b> , is back again on its basal position
<b>Moment to start the timer! 0 sec.</b>	<b>The timer is counting: 1,2,3,..</b>	<b>The timer stops: in health it stops between 3 and 4 seconds</b>

Figure 9f. Crucial moments for time's counting of duration: the moment when the stomach starts to move and the moment when the stomach returns in its basal position at rest.

## THE GASTRIC ASPECIFIC REFLEX

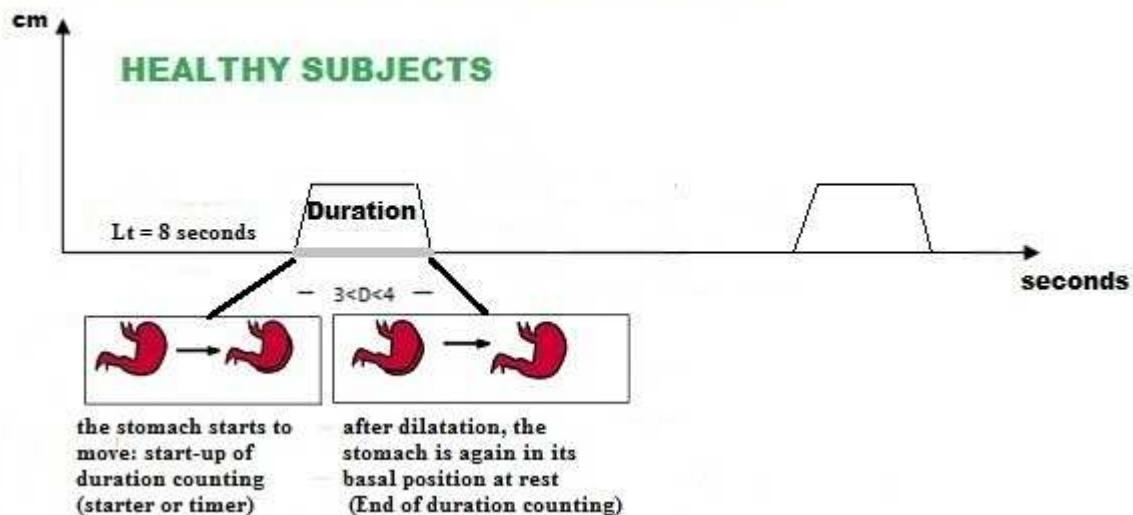


Figure 9g. 'Duration counting' starts-up when the stomach begins to move and it stops when the stomach returns to its basal position at rest (End of the first reflex)

In comparison with "healthy" parameters ( $3 < D < 4$ ), i.e., in healthy subjects the duration of the reflex is between 3 and 4 seconds, **the duration (D) of the reflex tends to augment** (Figure 9h, diagram below; Table 3, third column) in case of Inherited Real Risk of CAD ( $4 \text{ sec.} \leq D < 6 \text{ sec.}$ ), and it augments more and more (Table 3) in case of pathology with different growing values depending on its severity and clinical evolution (Pathology in evolution:  $6 < D \leq 7$ ); (advanced stages of pathology:  $D > 7$ ).

### Duration of Cardio-Gastric Aspecific Reflex

	Latency time (Lt)	Duration (D)
Healthy subject	Lt = 8	$3 < D < 4$
Inherited Real Risk of pathology (pre-clinical stages)	Lt = 8	$4 \leq D < 6$
Pathology (early clinical stages)	$7 < Lt \leq 8 \text{ sec.}$	$D \geq 6$
Pathology (in evolution)	$6 \leq Lt \leq 7 \text{ sec.}$	$6 < D \leq 7$
Pathology (advanced stages)	Lt < 6 sec.	$D > 7$

**Table 3.** Legend: Lt = Latency time of the reflex in seconds.; D = duration of the reflex in seconds.

Note the difference with the previous parameter of latency time: in case of pathology the latency time tends to diminish, but **the reflex's duration tends to augment** (Figure 9h).

**First Remarks:** Interestingly, latency time begins to lower only when duration of the reflex is more than 6 sec., showing that the slight lowering of tissue pH escapes the latency time!

### THE GASTRIC ASPECIFIC REFLEX

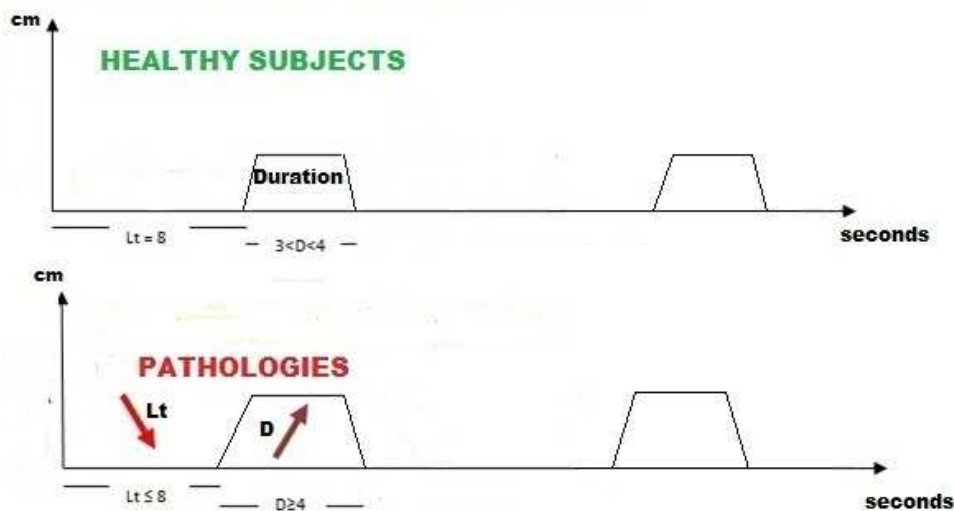


Figure 9h. Duration of reflex is between 3 and 4 seconds in healthy subjects, while it augments ( $D \geq 4$ ) in subjects with pathologies or at risk of pathology.

**Second Remarks:** You can note from Table 3 that when the reflex duration is more than or equal to the physiological one (physiologically, the duration of reflex is more than 3 and less than 4 seconds), i.e., between 4 and 6 seconds, this does not mean that immediately and automatically the latency time of the reflex is diminishing (Inherited Real Risk of pathology, Table 3, 3<sup>rd</sup> row). Only when the duration of the reflex is more than 6 seconds, when it crosses this critical value, the latency time starts to diminish (early clinical stage of pathology, Table 3, 4<sup>th</sup> row). When the duration of the reflex is between 4 and 6 seconds (Table 3, 3<sup>rd</sup> row), this is yet a pre-clinical stage (inherited real risk of cardiovascular disease). When the duration is 6 seconds or more, and the latency time starts to diminish (Table 3, 4<sup>th</sup> row), these critical values confirm the earlier clinical stage of the pathology (from pre-clinical to clinical stage), or a pathology in evolution or advanced overt disease (Table 3, 5<sup>th</sup> - 6<sup>th</sup> rows), as much as the duration values is growing.

### 9.3 Intensity of the cardio gastric aspecific reflex in Gentile's sign

The Intensity (I) of the cardio gastric reflex represents the maximal dilatation of the stomach and it is calculated in centimeters (Figure 9i, 9m).

#### THE GASTRIC ASPECIFIC REFLEX

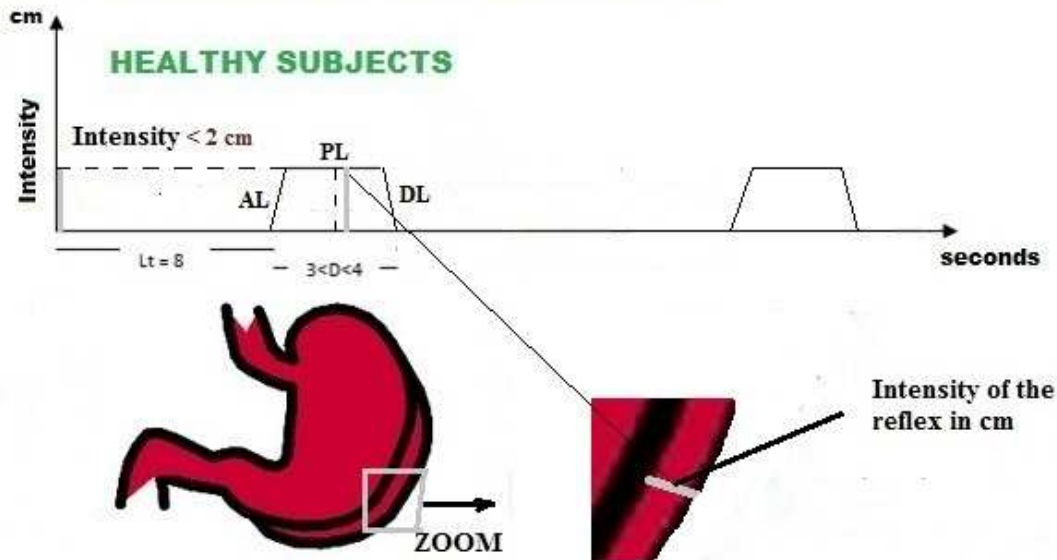


Figure 9i. Gentile's sign: the Intensity (I) of the reflex is less than 2 cm in healthy subjects.

#### How to measure the Intensity of the cardio-gastric aspecific reflex in Gentile's sign




		
1. The stomach <b>begins</b> the dilatation, it is reaching its maximal dilatation	2. The <b>stomach</b> reaches its maximal dilatation (plateau line – PL - of dilatation)	3. The <b>stomach</b> is returned, is <b>back again on its basal position</b>
<i>Do not measure the intensity of reflex in the ascending line (AL) of dilatation (Figure 9i)</i>	<i>This is the moment to measure the intensity of the reflex, plateau line (PL) of the dilatation (Figure 9i)</i>	<i>Do not measure the intensity of reflex in the descending line (DL) of dilatation (Figure 9i)</i>

Figure 9i. Crucial moments for the measure of the intensity of the reflex: take the measure in the plateau line (PL) of the reflex's duration, during when the stomach reaches its maximal dilatation.

With respect to the “healthy” parameters ( $I < 2 \text{ cm}$ ), the intensity (I) of the reflex tends to augment ( $2 \text{ cm} \leq I < 5 \text{ cm}$ ) in case of Inherited Real Risk of CAD (Figure 9l; Table 4, fourth column), and it augments more and more in case of pathology with different growing values depending on its severity and clinical evolution ( $I \geq 5 \text{ cm}$ ) (Figure 9m), i.e., (Pathology in evolution:  $6 \leq I < 7$ ); (advanced stages of pathology:  $I > 7 \text{ cm}$ ).

### Intensity of Cardio-Gastric Aspecific Reflex

	<i>Lt</i>	<i>D</i>	<i>Intensity</i>
<i>Healthy subject</i>	$Lt = 8$	$3 < D < 4$	$I < 2 \text{ cm}$
<i>Inherited Real Risk of pathology (pre-clinical stages)</i>	$Lt = 8$	$4 \leq D < 6$	$2 \leq I < 5$
<i>Pathology (early clinical stages)</i>	$7 < Lt \leq 8 \text{ sec.}$	$D \geq 6$	$5 \leq I < 6$
<i>Pathology (in evolution)</i>	$6 \leq Lt \leq 7 \text{ sec.}$	$6 < D \leq 7$	$6 \leq I < 7$
<i>Pathology (advanced stages)</i>	$Lt < 6 \text{ sec.}$	$D > 7$	$I > 7 \text{ cm}$

**Table 4. Intensity in Gentile's sign.** Legend: *Lt* = Latency time in sec.; *D* = duration in sec; *I* = intensity in centimeters.

## THE GASTRIC ASPECIFIC REFLEX

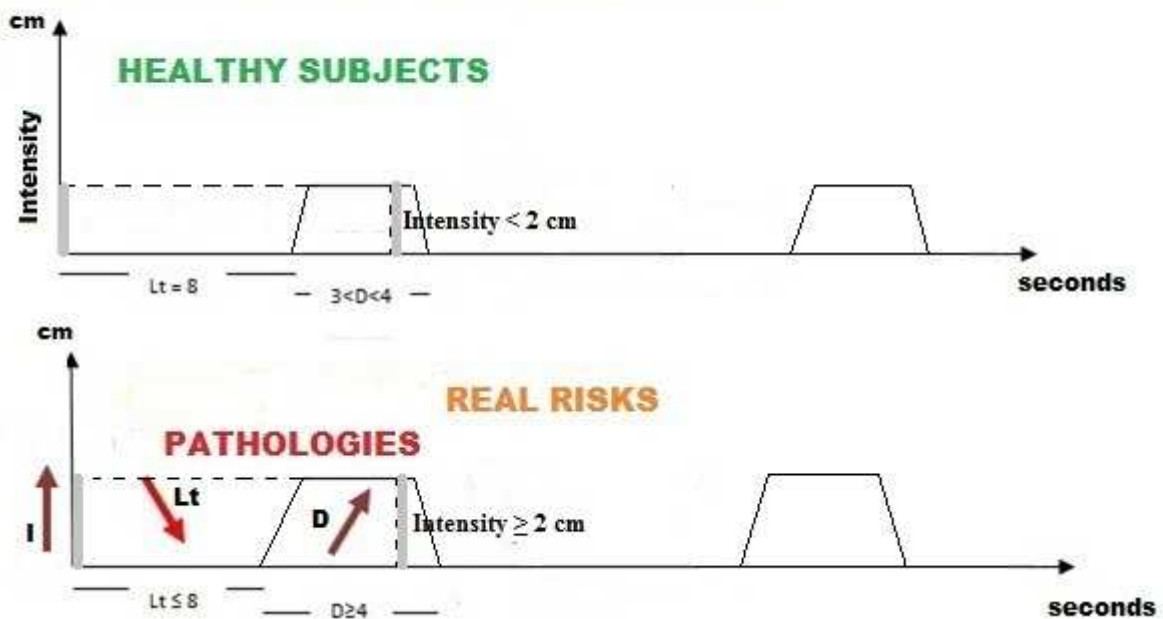


Figure 9m. Gentile's sign. Intensity (*I*) of reflex is less than 2 cm in healthy subjects, while it augments ( $I \geq 2 \text{ cm}$ ) in subjects at risk of pathology, and more and more in subject with overt disease.

You can note that the **intensity** of the reflex, as the duration of the reflex, **augments** in case of Inherited Real Risk ( $2 \leq I < 5$ ), and more and more in case of pathology with different growing values depending on its severity and clinical evolution ( $I \geq 5$ ) (Figure 9m).

In case of Inherited Real Risk (IRR) of Coronary Artery Disease (CAD) we can distinguish between IRR of CAD with risk of Acute Myocardial Infarction (AMI) and without any risk of AMI (see Appendix B).

## 9.4 'Differential latency time' of the cardio gastric aspecific reflex in Gentile's sign

The **differential latency time (dlt)** is calculated counting the seconds passing from the moment in which the first reflex disappears (the stomach after the dilatation comes back to its basal position at rest) to the beginning of the second reflex. The timer (seconds counting) starts from the exact moment in which the stomach comes back to the basal position at rest, and it stops in the exact moment in which the stomach starts his second dilatation (Figure 9n, Figure 9o).

### How to measure the differential latency time of the cardio-gastric reflex in Gentile's sign

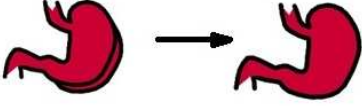


		
1. The stomach <b>finishes</b> the dilatation. End of first reflex	2. The stomach is back again on its basal position	3. The stomach starts to dilate again. Beginning of second reflex
<b>Moment to start the timer! 0 sec.</b>	<b>The timer is counting: 1,2,3,..</b>	<b>The timer stops: in health it stops between exactly after 16 seconds</b>

Figure 9n. Crucial moments for the measure of the differential latency time of the reflex.

## THE GASTRIC ASPECIFIC REFLEX

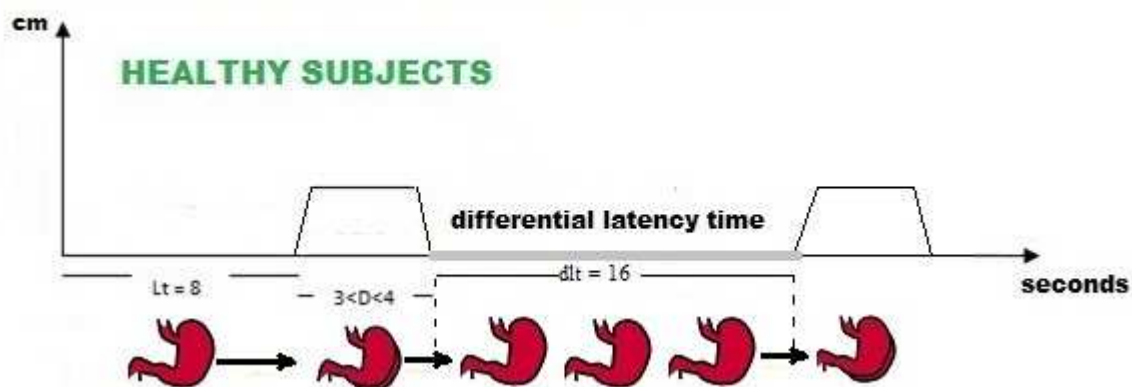


Figure 9o. Gentile's sign. Disappearing latency time (dlt) of the reflex is exactly 16 seconds in healthy subjects.

The disappearing latency time is the pause between 2 cardio – gastric reflexes. We start to count the seconds elapsing from the end of the 1<sup>st</sup> reflex to the beginning of the 2<sup>nd</sup> reflex.

# THE GASTRIC ASPECIFIC REFLEX

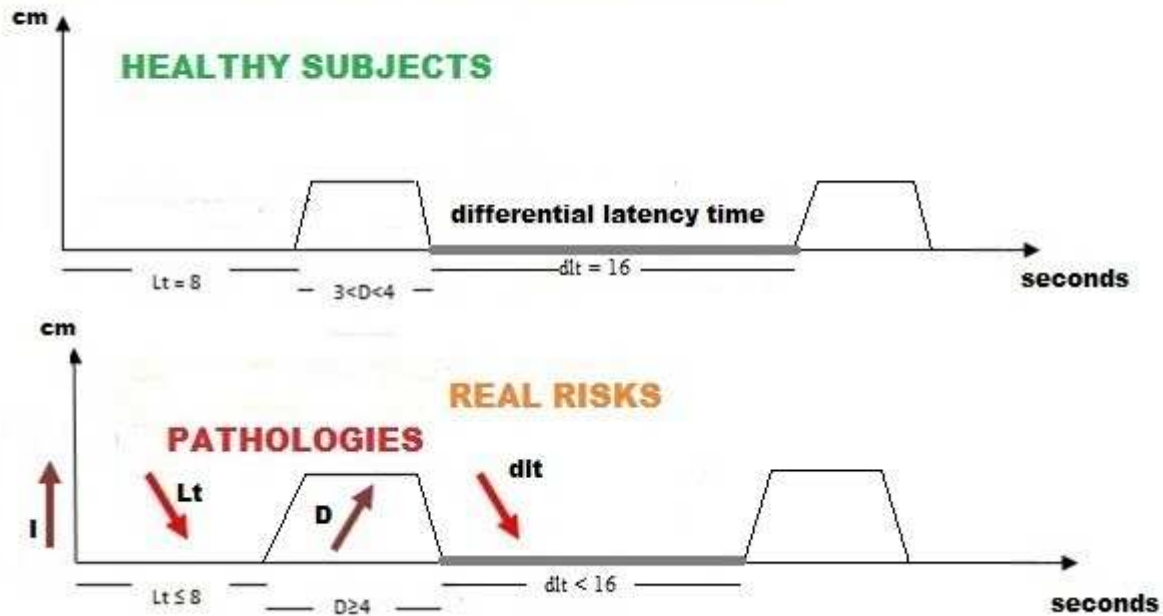


Figure 9p. Gentile's sign. Disappearing latency time ( $dlt$ ) of the reflex is exactly 16 seconds in healthy subjects, while it subjects with Inherited Real Risk of CAD is less than 16 seconds, it diminishes more and more in case of pathology.

With respect to the "healthy" parameters ( $dlt = 16$  seconds), the differential latency time ( $dlt$ ) of the reflex tends to diminish (Figure 9p; Table 5, fifth column) in case of Inherited Real Risk of CAD ( $10 \leq dlt < 16$ ), and it diminishes more and more in case of pathology ( $3 < dlt < 10$  seconds), with different decreasing time's values depending on its severity and clinical evolution, i.e., (early clinical stage of pathology:  $8 \leq dlt < 10$ ); (Pathology in evolution:  $5 \leq dlt < 8$ ); (advanced stages of pathology:  $3 \leq dlt < 5$ ).

**Differential latency time ( $dlt$ ) of Cardio-Gastric Aspecific Reflex**

	$Lt$	$D$	$I$	$dlt$
Healthy subject	$Lt = 8$ sec.	$3 < D < 4$	$I < 2$	$dlt = 16$ sec.
Inherited Real Risk of pathology (pre-clinical stages)	$Lt = 8$ sec.	$4 \leq D < 6$	$2 \leq I < 5$	$10 \leq dlt < 16$
Pathology (early clinical stages)	$7 < Lt \leq 8$ sec.	$D \geq 6$	$5 \leq I < 6$	$8 \leq dlt < 10$
Pathology (in evolution)	$6 \leq Lt \leq 7$ sec.	$6 < D \leq 7$	$6 \leq I < 7$	$5 \leq dlt < 8$
Pathology (advanced stages)	$Lt < 6$ sec.	$D > 7$	$I > 7$	$3 \leq dlt < 5$

**Table 5.** Legend:  $Lt$  = Latency time in sec.;  $D$  = duration in sec.;  $I$  = intensity;  $dlt$  = differential latency time in sec.

## 9.5 Tonic Gastric Contraction in Gentile's sign



Figure 9q. Stomach's contraction

The tonic gastric contraction is a paramount diagnostics parameter in cardio-gastric aspecific reflex diagnostics (Gentile's sign), especially to easily diagnose an overt severe cardiovascular pathology. The tonic gastric contraction refers to the quick contraction of the stomach after its first dilatation and it occurs just in the case evidenced in Table 6, i.e., cardiovascular pathology in advanced clinical stage. See the animation where there is tonic gastric contraction – tGC -, i.e., the stomach after dilatation, not only comes back to its basal position, but even it contracts itself.

[http://www.sisbq.org/cardiogastricreflex\\_overtcad.html](http://www.sisbq.org/cardiogastricreflex_overtcad.html)

The Tonic Gastric Contraction in Gentile's sign

	<i>Lt</i>	<i>D</i>	<i>I</i>	<i>dlt</i>	<i>tGC</i>
<i>Healthy subject</i>	<i>Lt = 8 sec.</i>	<i>3 &lt; D &lt; 4</i>	<i>I &lt; 2</i>	<i>dlt = 16 sec.</i>	<b>No</b>
<i>Inherited Real Risk of CAD (pre-clinical stages)</i>	<i>Lt = 8 sec.</i>	<i>4 ≤ D &lt; 6</i>	<i>2 ≤ I &lt; 5</i>	<i>10 ≤ dlt &lt; 16</i>	<b>No</b>
<i>Pathology (early clinical stages)</i>	<i>7 &lt; Lt ≤ 8 sec.</i>	<i>D ≥ 6</i>	<i>5 ≤ I &lt; 6</i>	<i>8 ≤ dlt &lt; 10</i>	<b>No</b>
<i>Pathology (in evolution)</i>	<i>6 ≤ Lt ≤ 7 sec.</i>	<i>6 &lt; D ≤ 7</i>	<i>6 ≤ I &lt; 7</i>	<i>5 ≤ dlt &lt; 8</i>	<b>No</b>
<i>Pathology (advanced stages)</i>	<i>Lt &lt; 6 sec.</i>	<i>D &gt; 7</i>	<i>I &gt; 7</i>	<i>3 ≤ dlt &lt; 5</i>	<b>Yes</b>

**Table 6.** Legend: *Lt* = Latency time in sec.; *D* = duration in sec.; *I* = intensity; *dlt* = differential latency time in sec.; *tGC* = tonic gastric contraction.

Importantly, **tonic gastric contraction** appears when **latency time lowers under 6 sec.**, indicating intense tissue acidosis.

## 9.6 Summary

In summary, depending on the patient we can observe different cases: healthy subjects, subjects at inherited real risk of cardiovascular pathologies (pre-clinical stages), subjects with pathology (early stages, even silent and asymptomatic; in evolution stage; overt disease).

We present some of these cases in the following animations with the related diagnostics parameter of interest (Latency time, duration, intensity, differential latency time, tonic



gastric contraction) resumed in Figure 9r, with a comparison between healthy subjects and subjects at risk of pathology or with disease in evolution.

## THE GASTRIC ASPECIFIC REFLEX

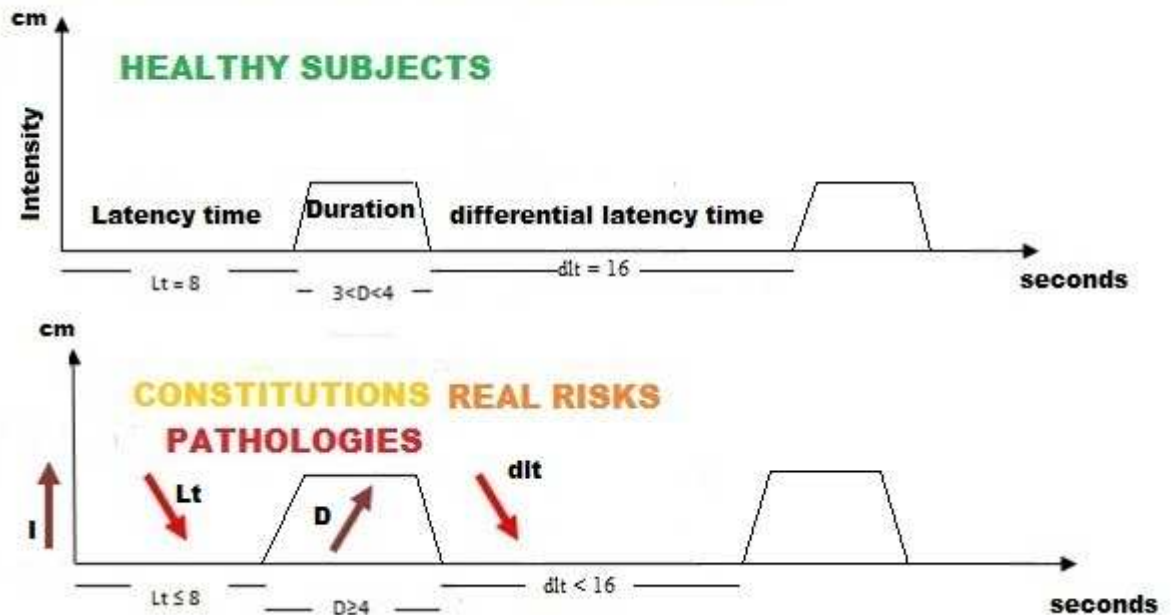


Figure 9r. Legend: I = Intensity; Lt = Latency time; D = Duration; dlt = differential latency time.

### Animations

- 1) Healthy subjects: [http://www.sisbq.org/cardiogastricreflex\\_health.html](http://www.sisbq.org/cardiogastricreflex_health.html)  
(Latency time,  $Lt = 8$  seconds; Duration:  $3 \text{ s} < D < 4 \text{ s}$ ; Intensity:  $I < 2 \text{ cm}$ ;  $dlt = 16$  seconds; no tonic gastric contraction);
- 2) CAD pathology in early stages: [http://www.sisbq.org/cardiogastricreflex\\_earlycad.html](http://www.sisbq.org/cardiogastricreflex_earlycad.html)  
(Latency time:  $Lt < 8$  seconds; Duration:  $D \geq 6 \text{ s}$ ; Intensity:  $I > 5 \text{ cm}$ ;  $8 \leq dlt \leq 10$  seconds; no tonic gastric contraction);
- 3) CAD overt pathology: [http://www.sisbq.org/cardiogastricreflex\\_overtcad.html](http://www.sisbq.org/cardiogastricreflex_overtcad.html)  
(Latency time:  $Lt < 6$  seconds; Duration:  $D > 7 \text{ s}$ ; Intensity:  $I > 7 \text{ cm}$ ;  $dlt < 5$  seconds);

and there is tonic gastric contraction – tGC -, i.e., the stomach after dilation, not only comes back to its basal position, but even it contracts itself).

In order to better understand the dynamics of cardio-gastric aspecific reflex and its related parameter please have a look at the following animations.

CARDIO-GASTRIC ASPECIFIC REFLEX (MEAN PRESSURE): DILATATION OF THE STOMACH IN HEALTHY SUBJECTS

[http://www.sisbq.org/cardiogastricreflex\\_health.html](http://www.sisbq.org/cardiogastricreflex_health.html)

CARDIO-GASTRIC ASPECIFIC REFLEX (MEAN PRESSURE): CAD PATHOLOGY IN EARLY STAGE

[http://www.sisbq.org/cardiogastricreflex\\_earlycad.html](http://www.sisbq.org/cardiogastricreflex_earlycad.html)

CARDIO-GASTRIC ASPECIFIC REFLEX (MEAN PRESSURE): OVERT CAD PATHOLOGY (ADVANCED STAGES)

[http://www.sisbq.org/cardiogastricreflex\\_overtcad.html](http://www.sisbq.org/cardiogastricreflex_overtcad.html)



*Figure 9s. Stomach at rest. basal*



*Figure 9t. Stomach dilated*



*Figure 9u. tonic gastric contraction*

**Appendix A:**  
**The mathematical relations between the different parameters**

In Figure 9r and in Table 7, you can note the mathematical relations existing between the different parameters, already evidenced in Figure 9r (Figure 9r, diagram below).

**Mathematical relations of parameters in Gentile's sign**

	<i>Lt</i>	<i>D</i>	<i>I</i>	<i>dlt</i>
<i>Healthy subject</i>	<i>Lt = 8 sec.</i>	<i>3 &lt; D &lt; 4</i>	<i>I &lt; 2</i>	<i>dlt = 16 sec.</i>
<i>Inherited Real Risk of CAD (pre-clinical stages)</i>	<i>Lt = 8 sec.</i>	<i>4 ≤ D &lt; 6</i>	<i>2 ≤ I &lt; 5</i>	<i>10 ≤ dlt &lt; 16</i>
<i>Pathology (early clinical stages)</i>	<i>7 &lt; Lt ≤ 8 sec.</i>	<i>D ≥ 6</i>	<i>5 ≤ I &lt; 6</i>	<i>8 ≤ dlt &lt; 10</i>
<i>Pathology (in evolution)</i>	<i>6 ≤ Lt ≤ 7 sec.</i>	<i>6 &lt; D ≤ 7</i>	<i>6 ≤ I &lt; 7</i>	<i>5 ≤ dlt &lt; 8</i>
<i>Pathology (advanced stages)</i>	<i>Lt &lt; 6 sec.</i>	<i>D &gt; 7</i>	<i>I &gt; 7</i>	<i>3 ≤ dlt &lt; 5</i>

**Table 7.** Legend: *Lt* = Latency time in sec.; *D* = duration in sec.; *I* = intensity; *dlt* = differential latency time in sec.

The duration of the cardio gastric reflex is strictly related with the Microcirculatory Functional Reserve (MFR) and the fractal dimension (fD) of microvessels oscillations (vasomotility and vasomotion), finely diagnosed in 'Clinical Microangiology' (this is an fundamental brunch of Quantum Biophysical Semeiotics, depending on ureteral reflexes QBS diagnosis).

The duration of the cardio gastric aspecific reflex (in Gentile's sign) parallels the duration of Microcirculatory Functional Reserve (MFR), i.e., the duration in seconds of vasomotion 'diastole' (from lower ureteral QBS reflex it is the duration of opening of nutritional capillaries and venules, termed 'diastole of periphery heart' ). The inverse relation between fD and MFR, allows to deduce the fD just observing the duration of cardio-gastric aspecific reflex (Table 8).

Summarizing, if we refer to the fractal Dimension (fD), it is directly (d) or inversely (INV) related to:

- A) (INV) the local MFR (vasomotility and vasomotion) (Figure 9v, Table 8) and then
- B) (d) the presence, or not, of cardiovascular disease or inherited Real Risk of CAD;
- C) (d) the latency time (Lt) of H.A.G.R. (cardio-gastric aspecific reflex) and then to the tissue myocardial pH;
- D) (INV) the duration (D) of the cardio-gastric aspecific reflex.

If we compare the 2 diagrams (above and below) of Figure 9r, we can note the direct or inverse relations between the different parameters, and the differences between these parameters in healthy subjects, and in all other cases.

Latency time of the cardio-gastric reflex	Duration (D) of the reflex in Gentile's sign	MFR	Fractal dimation (fD)	Dynamics equilibria	State of health
Lt = 8 sec.	$3 < D < 4$	$3 < MFR < 4$	$fD \geq 3.81$	Chaotic attractor	Physiological condition – healthy state
Lt = 8 sec.	$3 < D \leq 4$	$3 < MFR < 4$	$3 < fD \leq 3.81$	Limit cycle tending to Chaotic attractor	Tendency to physiological conditions (potential phase, i.e., under pre-primary and primary prevention)
Lt = 8 sec.	$4 < D < 6$	$4 < MFR < 6$	$2 < fD \leq 3$	Limit cycle	Initial implementation of the tendency to disease – potential pathology (i.e., Inherited Real Risk of CAD) – initial evolution to disease
Lt < 8 sec.	$6 \leq D \leq 7$	$6 < MFR \leq 7$	$1 < fD \leq 2$	Limit cycle tending to fix point	Pathology – tendency to chronic disease, state of variable severity of disease evolution
Lt < 6 sec.	$D > 7$	$MFR > 7$	$fD = 1$	Fix point	Chronic disease – chronic acute pathology

**Table 8.** Relations between fractal dimension of microvessels oscillations and cardio-gastric reflex parameters. Legend: Lt = latency time in seconds, D = duration in seconds; MFR = microcirculatory functional reserve (related to vasomotility and vasomotion in Clinical Microangiology); fD = fractal dimension of microvessel oscillations dynamics.

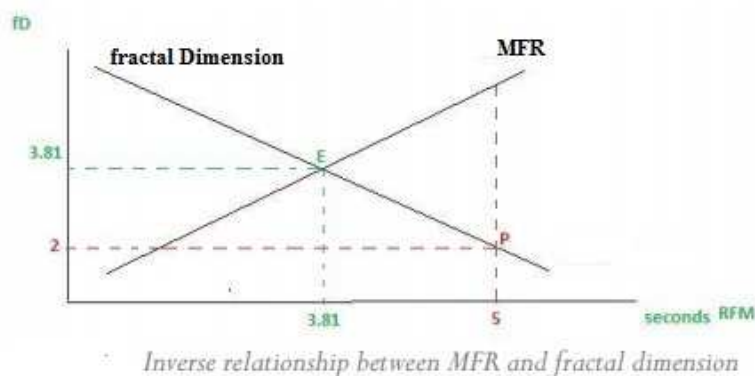


Figure 9v. Inverse relation between Microcirculatory Functional Reserve (MFR) and fractal dimension (fD)

## Appendix B:

### IRR of CAD with predisposition to AMI and without any risk of AMI

In case of Inherited Real Risk (IRR) of Coronary Artery Disease (CAD) we can distinguish between IRR of CAD with risk of Acute Myocardial Infarction (AMI) and without any risk of AMI.

You can note that the **intensity** of the reflex (paragraph 9.3), **augments** in case of Inherited Real Risk of CAD ( $2 \leq I < 5$ ). How can we distinguish between Inherited Real Risk of CAD with risk of AMI and Inherited Real Risk of CAD without any risk of AMI?

We can do it observing the exact intensity in cm, both in Caotino's sign and in Gentile's sign, so that we can divide the Inherited Real Risk of CAD into 2 sub-intervals (see Table 9).

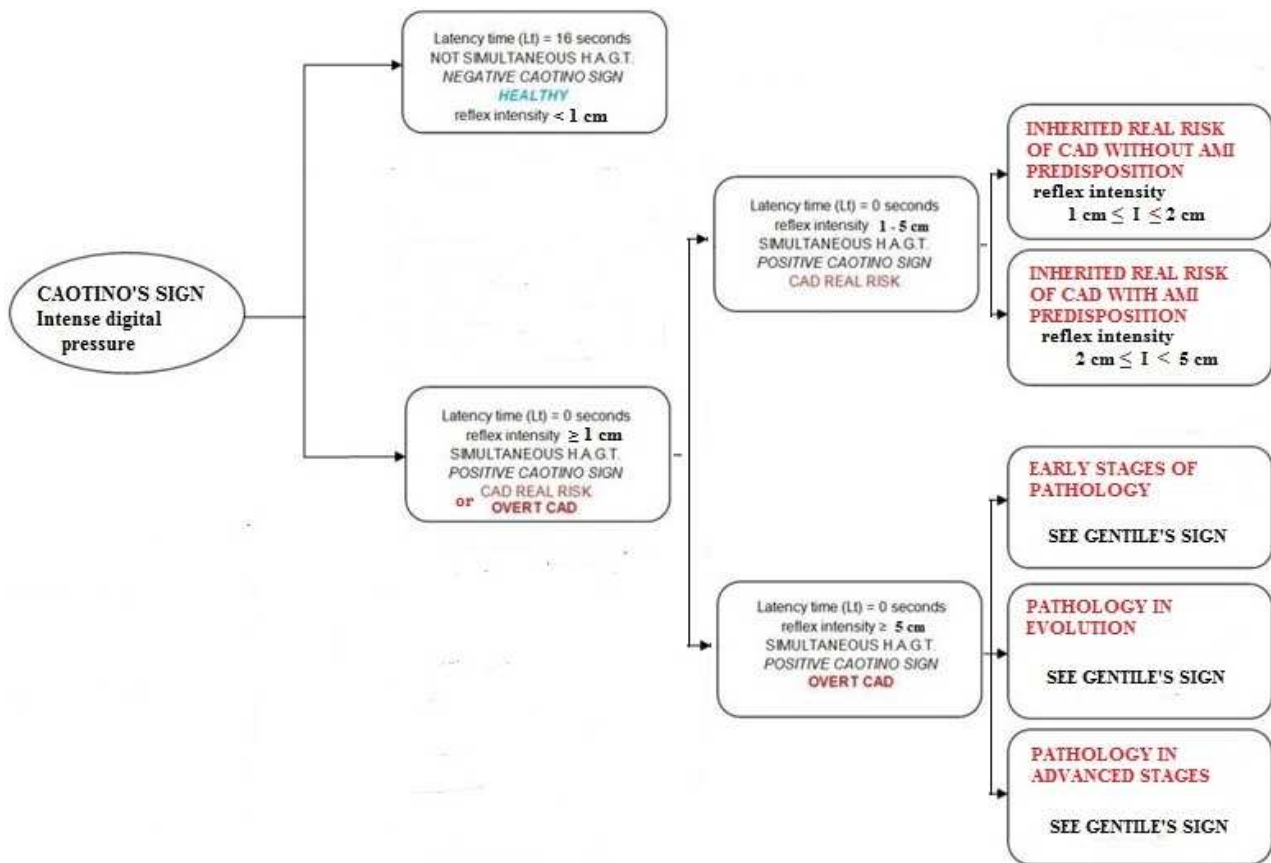
	CAOTINO'S	SIGN		GENTILE'S	SIGN		
	Latency time (Lt) in seconds	Intensity (I) in cm		Latency time (Lt) in seconds	Latency time (Lt) after preconditioning (pause of 5 sec.)	Duration (D) in seconds	Intensity (I) in cm
Healthy subject	Lt = 16 sec	$I \leq 1$ cm		Lt = 8	Lt = 16	$3 < D < 4$	$I < 2$ cm
Inherited Real Risk of CAD (without predisposition to AMI)	Lt = 0 sec	$1 \text{ cm} < I < 2 \text{ cm}$		Lt = 8	$13 < Lt < 15$	$4 \leq D < 5$	$I \geq 2 \text{ cm}$ $I < 3 \text{ cm}$
Inherited Real Risk of CAD (with predisposition to AMI)	Lt = 0 sec	$2 \text{ cm} \leq I \leq 5 \text{ cm}$		Lt = 8	Lt $\leq 12$	$5 \leq D \leq 6$	$I > 3 \text{ cm}$ $I < 5 \text{ cm}$

Table 9. Differential diagnosis of IRR of CAD without predisposition to AMI and with predisposition to AMI.

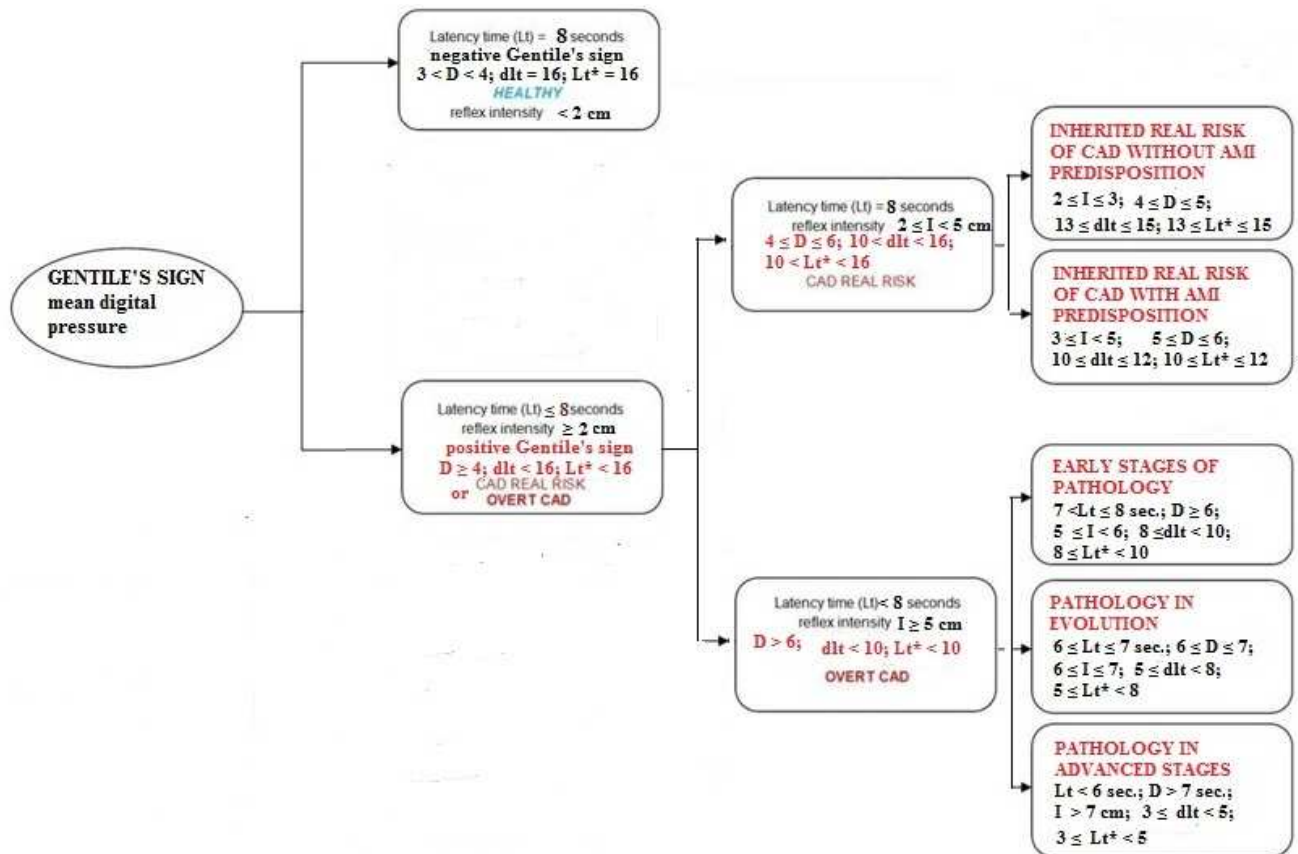
In case of positive Caotino's sign, if the intensity of the reflex in cm is between 1 cm and 2 cm, then there is Inherited Real Risk of CAD without predisposition to AMI, while if the intensity of the reflex in cm is between 2 cm and 5 cm, then there is Inherited Real Risk of CAD with predisposition to AMI.

Analogously, if the physician performs the Gentile's sign, a latency time between 13 seconds and 15 seconds, a Duration of the reflex between 4 and 5 seconds and an intensity between 2 cm and 3 cm is sign of Inherited Real Risk of CAD without predisposition to AMI, while a latency time less than 12 seconds, a duration of the reflex between 5 seconds and 6 seconds and an intensity between 3 cm and 5 cm is sign of Inherited Real Risk of CAD with predisposition to AMI.

Scheme 1 and Scheme 2 resume in flux diagrams all the parameters discussed in chapter 9 and in this appendix.



**Scheme 1.** Legend:  $Lt$  = latency time of the reflex in seconds;  $I$  = intensity of the reflex in centimeters.



**Scheme 2.** Legend:  $Lt$  = latency time of the reflex in seconds;  $D$  = duration of the reflex in seconds;  $dlt$  = differential latency time in seconds;  $Lt^*$  = latency time after preconditioning;  $I$  = intensity of the reflex in cms.

**Appendix C:**  
**Maneuvers to exclude the ‘false negative’ cases**

The negative signs assessed with QBS, have always to be confirmed with stress tests in order to exclude the ‘false negative’ cases (about 10%).

For example, in case of negative Caotino’s sign (see step 8), the physician must repeat the diagnosis with one of the two following maneuvers’:

a) **Bardi Manouvre, suggested by Stagnaro:**

mean-intense, NOT “intense”, digital pressure for 10 seconds, before repeating the Auscultatory Percussion for the diagnosis of Caotino’s sign, applied on the skin projection of GH neural center Figure ac1, 2cm above the external auditory meatus).

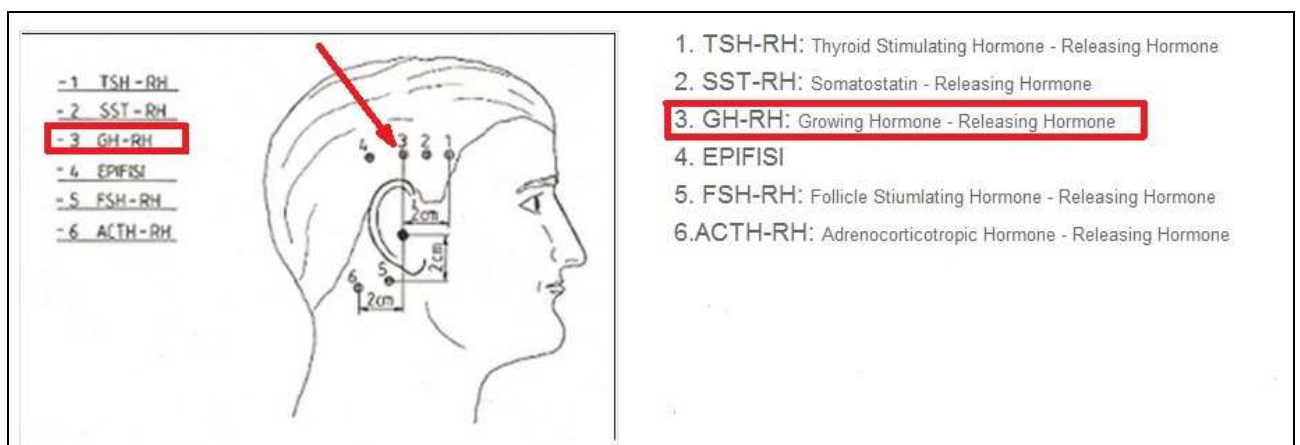


Figure ac1

b) **Restano’s Manouvre:**

this is a combination of 2 tests: the apnea test and the boxer test.

b.1) Apnea test: the physician invites the patient to not breath (apnea test) for all the time of the Auscultatory Percussion (Figure ac2);



Figure ac2

b.2) Boxer test: The patient hardly squeezes a hand (fist) and the sympathetic hypertonus appears (Figure ac3).



*Figure ac3*

The **Restano's Manoeuvre** has to be associated with the **Endogenous Adiponectin Test** (Figure ac4, mean-intense pinching of the skin and subcutaneous of lateral-abdominal region).



*Figure ac4*

The Restano's Manoeuvre associated with Endogenous Adiponectin Test, although quite complex, is really efficient in bedside recognizing the false-negative cases.

## References

- [1] Maguire R. On PALPATION and AUSCULTATORY PERCUSSION. Br Med J. 1898 Feb 19;1(1938):484-5. No abstract available. [PubMed - indexed for MEDLINE]
- [2] Broadbent WH. Note on Auscultatory Percussion and the Schott Treatment of Heart Disease. Br Med J. 1896 Mar 28;1(1839):769-70.
- [3] Gilbert VE. Detection of the liver below the costal margin: comparative value of palpation, light percussion, and auscultatory percussion. South Med J. 1994 Feb;87(2):182-6.[PubMed - indexed for MEDLINE]
- [4] Yernault JC, Bohadana AB. Chest Percussion. European Respiratory Journal,ERS Journals Ltd, 1995.
- [5] Brunk SF. Auscultatory percussion: an added dimension in physical diagnosis. Int J Clin Pract. 2003 Apr;57(3):204-9.
- [6] Guarino JR. Auscultatory percussion. A new aid in the examination of the chest. J Kans Med Soc. 1974 Jun;75(6):193-4. [PubMed - indexed for MEDLINE]
- [7] Guarino JR. Auscultatory percussion of the chest. Lancet. 1980 Jun 21;1(8182):1332-4. [PubMed - indexed for MEDLINE]
- [8] Guarino JR. Auscultatory percussion of the bladder to detect urinary retention. N Engl J Med. 1981 Sep 17;305(12):701. [PubMed - indexed for MEDLINE]
- [9] Guarino JR. Auscultatory percussion of the head. Br Med J (Clin Res Ed). 1982 Apr 10;284(6322):1075-7. [PubMed - indexed for MEDLINE]
- [10] Guarino JR. Auscultatory percussion of the urinary bladder. Arch Intern Med. 1985 Oct;145(10):1823-5. [PubMed - indexed for MEDLINE]
- [11] Guarino JR. Auscultatory percussion to detect ascites. N Engl J Med. 1986 Dec 11;315(24):1555-6. [PubMed - indexed for MEDLINE]
- [12] Guarino JR, Guarino JC. Auscultatory percussion: a simple method to detect pleural effusion.



- J Gen Intern Med. 1994 Feb;9(2):71-4. [PubMed - indexed for MEDLINE]
- [13] Stagnaro S., Rivalutazione e nuovi sviluppi di un fondamentale metodo diagnostico: la percussione ascoltata Atti Accademia Ligure di Scienze e Lettere. Vol. XXXIV, 1978.
- [14] Stagnaro S. Auscultatory Percussion of Rheumatic Diseases. X European Congress of Rheumatology. Moscow. 26 June-July, Proceedings, pg 175, 1983.
- [15] Stagnaro S. The percussion-auscultation syndrome in hyperfunction of the reticulo-histiocytic system. *Minerva Med.* 1983 Mar 10;74(9-10):479-80. [PubMed - indexed for MEDLINE]
- [16] Stagnaro S. Percussion auscultation of transient ischemic attacks. Role of cerebral evoked potentials. *Minerva Med.* 1985 Jun 16;76(25):1211-3. [PubMed - indexed for MEDLINE]
- [17] Stagnaro S. Il Ruolo della Percussione Ascoltata nella "difficile Diagnosi" di Appendicite. *Biol. Med.* 8, 71, 1986.
- [18] Stagnaro S. Auscultatory Percussion Therapeutic Monitoring and Cerebral Dominance in Rheumatology. 2nd World Congress of Inflammation, Antirheumatics, analgesics, immunomodulators. Abstracts, A. Book 1, pg. 116, March 19-22, Montecarlo, 1986.
- [19] Stagnaro Neri M, Stagnaro S. Functional dyspeptic syndrome caused by dyskinesia of the bile ducts. Auscultatory percussion diagnosis and therapeutic monitoring. *Clin Ter.* 1988 Dec 15;127(5):363-72. Review. [PubMed - indexed for MEDLINE]
- [20] Stagnaro MN, Stagnaro S. Early clinical diagnosis of osteoporosis using auscultatory percussion. Therapeutic monitoring. *Clin Ter.* 1991 Apr 15;137(1):21-7. Italian. [PubMed - indexed for MEDLINE]
- [21] Stagnaro-Neri M, Stagnaro S. Percussion-auscultation syndrome of carnitine deficiency *Clin Ter.* 1994 Aug;145(8):135-40. Italian.
- [22] Stagnaro S, Neri Stagnaro M. *Introduzione alla Semeiotica Biofisica.* Il Terreno Oncologico. Ed. Travel Factory, Rome, 2004.
- [23] Stagnaro S. *Single Patient Based Medicine.* Ed. Travel Factory, Rome, 2005.
- [24] Stagnaro S., Stagnaro-Neri M., *Basi microcircolatorie della semeiotica biofisica.* Atti del XVII Cong. Naz. Soc. Ital. Studio Microcircolazione, Firenze ott. 1995, Biblioteca Scient. Scuola Sanità Militare, 2, 94, 1995.
- [25] Stagnaro S., Stagnaro-Neri M., *Le Costituzioni Semeiotico-Biofisiche.* Strumento clinico fondamentale per la prevenzione primaria e la definizione della Single Patient Based Medicine. Travel Factory, Roma, 2004. [http://www.travelfactory.it/libro\\_costituzionisemeiotiche.htm](http://www.travelfactory.it/libro_costituzionisemeiotiche.htm)
- [26] Sergio Stagnaro, Simone Caramel (2013) . Inherited Real Risk of Coronary Artery Disease: pathophysiology, diagnosis and primary prevention. *Epidemiology and Cardiovascular Prevention.* Brief Communication. 8th International Congress of Cardiology in the internet. Published: 28 October 2013. FAC Federaciòn Argentina de Cardiologia [http://fac.org.ar/8cvc/llave/tl054\\_stagnaro/tl054\\_stagnaro.php - in pdf](http://fac.org.ar/8cvc/llave/tl054_stagnaro/tl054_stagnaro.php_in_pdf)
- [27] Sergio Stagnaro and Simone Caramel (2013). The Inherited Real Risk of Coronary Artery Disease, *Nature PG., EJCN, European Journal Clinical Nutrition,* Nature PG, 013 Apr 24. doi: 10.1038/ejcn.2013.37. [Pub-Med indexed for Medline] [Nature link](#)
- [28] Sergio Stagnaro and Simone Caramel (2013). The Inherited Real Risk of Coronary Artery Disease, *Nature PG., European Journal of Clinical Nutrition* 67, 683 (June 2013) | doi:10.1038/ejcn.2013.37 <http://www.nature.com/ejcn/journal/v67/n6/full/ejcn201337a.html> [MEDLINE].
- [29] Simone Caramel and Sergio Stagnaro (2012). Vascular calcification and Inherited Real Risk of lithiasis. *Front. In Encocrinology* [http://www.frontiersin.org/Bone\\_Research/10.3389/fendo.2012.00119/full](http://www.frontiersin.org/Bone_Research/10.3389/fendo.2012.00119/full) [MEDLINE].
- [30] Sergio Stagnaro and Simone Caramel (2013) [Typical Microcirculatory Remodelling of CAD Inherited Real Risk.](#) *Journal of QBS.* <http://www.sisbq.org/uploads/5/6/8/7/5687930/mccad.pdf>
- [31] Sergio Stagnaro and Simone Caramel. The Key Role of Vasa Vasorum Inherited Remodeling in QBS Microcirculatory Theory of Atherosclerosis. *Frontiers in Epigenomics and Epigenetics.* [http://www.frontiersin.org/Epigenomics\\_and\\_Epigenetics/10.3389/fgene.2013.00055/full](http://www.frontiersin.org/Epigenomics_and_Epigenetics/10.3389/fgene.2013.00055/full) [MEDLINE]
- [32] Stagnaro Sergio. CAD Inherited Real Risk, Based on Newborn-Pathological, Type I, Subtype B, Aspecific, Coronary Endoarteriolar Blocking Devices. Diagnostic Role of Myocardial Oxygenation and Biophysical-Semeiotic Preconditioning *International Atherosclerosis Society, IAS,* [www.athero.org](http://www.athero.org), 29 April, 2009 <http://www.athero.org/commentaries/comm907.asp>

- [33] Sergio Stagnaro Reale Rischio Congenito di Infarto miocardio Fondamentali Aspetti Teorici. [www.sisbq.org](http://www.sisbq.org), [http://www.sisbq.org/uploads/5/6/8/7/5687930/rrcinfartomiocardio\\_aspettiteorici.pdf](http://www.sisbq.org/uploads/5/6/8/7/5687930/rrcinfartomiocardio_aspettiteorici.pdf)
- [34] Sergio Stagnaro. Reale Rischio Congenito di Infarto Miocardio. Diagnosi e Terapia. [www.sisbq.org](http://www.sisbq.org), [http://www.sisbq.org/uploads/5/6/8/7/5687930/rrcinfartomiocardio\\_aspettiteorici.pdf](http://www.sisbq.org/uploads/5/6/8/7/5687930/rrcinfartomiocardio_aspettiteorici.pdf)
- [35] Sergio Stagnaro and Simone Caramel (2012). Allegra's Syndrome plays a central Role in bedside clinical Diagnostics. [www.sisbq.org](http://www.sisbq.org), *Journal of Quantum Biophysical Semeiotics*, <http://www.sisbq.org/uploads/5/6/8/7/5687930/allegrasyndrome.pdf>
- [36] Sergio Stagnaro. Without CAD Inherited Real Risk, All Environmental Risk Factors of CAD are innocent Bystanders. *Canadian Medical Association Journal*. CMAJ, 14 Dec 2009, <http://www.cmaj.ca/cgi/eletters/181/12/E267#253801>
- [37] Sergio Stagnaro. I Segni di Caotino\* e di Gentile\*\* nella Diagnosi di Reale Rischio Congenito di CAD e di Infarto Miocardico, ancorché iniziale o silente. Fisiopatologia e Terapia. *Lectio Magistralis*. III Convegno della SISBQ, 9-10 Giugno 2012, Porretta Terme (Bologna). [www.sisbq.org](http://www.sisbq.org). [http://www.sisbq.org/uploads/5/6/8/7/5687930/presentazione\\_stagnaro\\_it.pdf](http://www.sisbq.org/uploads/5/6/8/7/5687930/presentazione_stagnaro_it.pdf) ; English version: [http://www.sisbq.org/uploads/5/6/8/7/5687930/presentazione\\_stagnaro\\_eng.pdf](http://www.sisbq.org/uploads/5/6/8/7/5687930/presentazione_stagnaro_eng.pdf)

## Video-References

- [V1] Stagnaro S. Interview to Dr Sergio Stagnaro. (subtitled in English). April 2010, Riva Trigoso, Italy. <http://www.youtube.com/watch?v=F9gySMQuGBY>
- [V2] Stagnaro S. Inherited Real Risk of CAD. The sign of Caotino (subtitled in English) 2° SISBQ conference. May, 2011. Chiusi, Italy. <http://www.youtube.com/watch?v=eGQVJuLf0Ko>
- [V3] Stagnaro Neri M. Storia della Semeiotica Biofisica di Stagnaro. I° corso di formazione SBQ. Roma, 10 novembre 2013 <http://www.youtube.com/watch?v=AmiuF83B6ys>
- [V4] Siniscalchi M. Introduzione alla percussione ascoltata. I° corso di formazione SBQ. Roma, 10 novembre 2013 <http://www.youtube.com/watch?v=qrb2bkLoCTA>
- [V5] Caramel S. Senso e significato del segno di Caotino: l'informazione SBQ. I° corso di formazione SBQ. Roma, 10 novembre 2013 <http://www.youtube.com/watch?v=M0NIhKG3zn0>
- [V6] Rinaldi M. Il segno di Caotino: applicazioni pratiche. I° corso di formazione SBQ. Roma, 10 novembre 2013 <http://www.youtube.com/watch?v=Klcslyt3FDQ>
- [V7] Musella F. Riflesso gastrico aspecifico: applicazioni pratiche. I° corso di formazione SBQ. Roma, 11 novembre 2013 <http://www.youtube.com/watch?v=OK8Udh7vdSo>
- [V8] Stagnaro S. Senso e significato del riflesso gastrico aspecifico. I° corso di formazione SBQ. Roma, 11 novembre 2013 <http://www.youtube.com/watch?v=PfACBB6tb8M>

## Other sources

Dr. Sergio Stagnaro

Official website – <http://www.semeioticabiofisica.it>

International Society of Quantum Biophysical Semeiotics (SISBQ)

Official website <http://www.sisbq.org>

Dr. Sergio Stagnaro blog - <http://sergiostagnaro.wordpress.com/>

Contacts e-mail [info.sisbq@gmail.com](mailto:info.sisbq@gmail.com)