

# **Arrhythmogenic Right Ventricular Dysplasia/Cardiomyopathy Bedside Diagnosis. Morosini's Syndrome.**

**Sergio Stagnaro\***  
**Simone Caramel\*\***

## **Introduction**

Arrhythmogenic Right Ventricular Dysplasia (ARVD), also termed Arrhythmogenic Right Ventricular Cardiomyopathy (ARVC), is right ventricle myocardial disorder, whose causes are unknown, showing a frequent familial occurrence (1-5). The typical clinical manifestation consists of ventricular arrhythmias with a left bundle branch block (LBBB) pattern that occur predominantly in young adults. ARVD may result in sudden death, which occurs in up to 80% of diseased individuals. Other manifestations are electrocardiographic repolarization and depolarization changes (epsilon wave in lead V<sub>2</sub> and an inversion of T waves in precordial leads V<sub>1</sub>-V<sub>3</sub>, frequent premature ventricular complexes (PVCs), ventricular tachycardia (VT), ventricular fibrillation (VF.), structural abnormalities that range from subtle wall aneurysms within the so-called "triangle of dysplasia" to biventricular regional or global dysfunction, and localized or widespread fibro-fatty infiltration of the right ventricular myocardium. Till now, the diagnosis of ARVD/C is difficult, and based on the presence of major and minor criteria encompassing genetic, electrocardiographic, pathophysiologic, and histopathologic factors. The imaging modalities used to evaluate right ventricular abnormalities include conventional angiography, echocardiography, radionuclide angiography, ultrafast computed tomography, and magnetic resonance (MR) imaging. Among these techniques, MR imaging allows the clearest visualization of the heart.

## **Morosini's Syndrome**

From the above remarks, it appears clear that in the majority of cases the right diagnosis of ARVD/C results nowadays after patient's death, with autopsy data.

Thanks to Quantum Biophysical Semeiotics, physicians are nowadays able to bedside recognise ARVD/C at individual's birth. In following, the QBS method, termed Morosini's Syndrome, is briefly described.

First, physician has to ascertain Caotino's Sign (6-14), showing in one second the presence of inherited heart disorder (Fig. 1 – Fig. 2). From the practical point of view, physician applies an "intense" digital pressure upon the heart projection area, i.e., precordium (6).

In health, "simultaneously", due to no-local realm, the gastric aspecific Reflex does not appear at all; Aspecific Gastric Reflex: in the stomach both fundus and body dilate, while antral pyloric region contracts, as Fig. 3 indicates.

## Heart Aspecific Gastric Reflex (H.A.G.R.) intense digital pression on precordium – Caotino sign

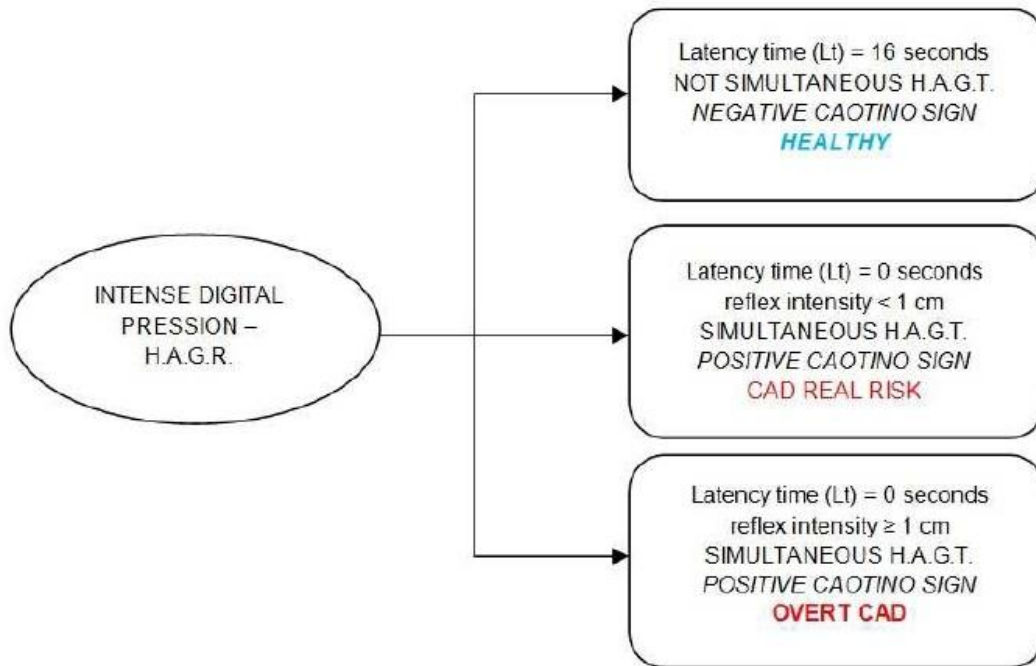


Figure 1

If Caotino’s Sign is negative at base assessment, we suggest to ascertain it under stress tests, as Apnoea Test, aiming to detect “latent, variant” form of CAD Inherited Real Risk.

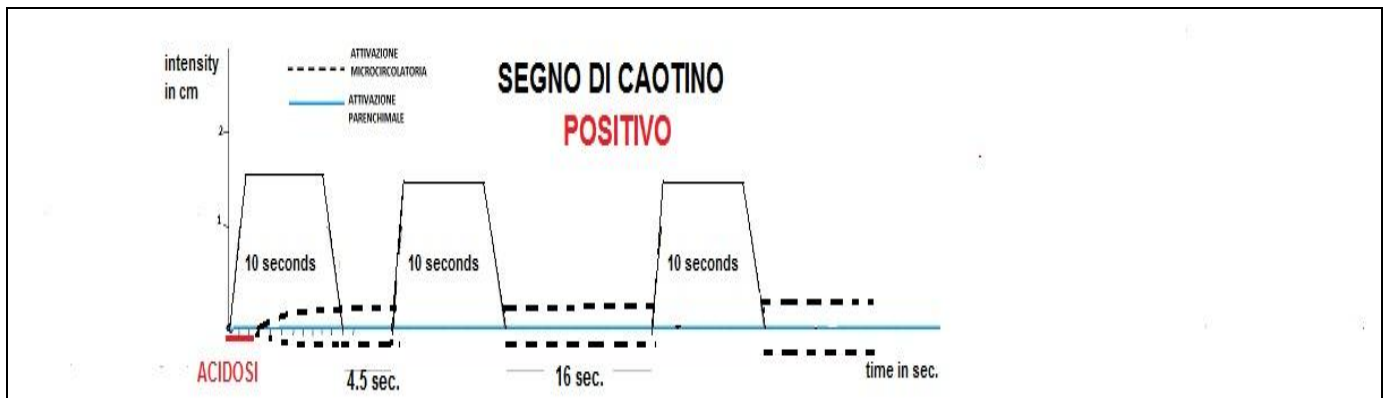


Figure 2

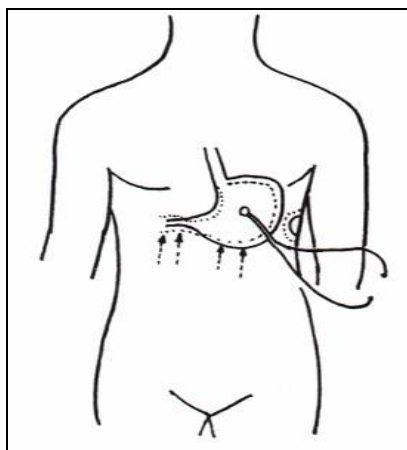


Figure 3

*Gastric aspecific Reflex: in the stomach both fundus and body dilate, while antral pyloric region contracts.*

On the contrary, in pathological situations, enlisted in Figure 4, “simultaneously” with the beginning of “intense” digital pressure stimulation, gastric aspecific Reflex appears, showing an intensity in cm., related to the seriousness of underlying heart disorder.

**Caotino’s Sign: Significances.**

- 1) CAD Inherited Real Risk (90%)
- 2) Arritmogenic QBS Constitution, ARVD/C, ...
- 3) Inter-Atrial and -Ventricular *Forum Pervium*
- 4) Diverse Valve Abnormality
- 5) Pericardium Disorders
- 6) Aneurism of Valsalva’ Sinus IIIa + v ...
- 7) AMI Outcome (tl 2 sec.; Int.  $\geq 1 < 3$  cm.)
- 8) Coronary Stent and other Devices (latency tyme 3 sec.; Intensity  $\geq 3$  cm.)

**And so on.**

Figure 4

In Figure 4 are summarised the significances of Caotino’s Sign. In 90% of all cases it indicates the presence of CAD Inherited Real Risk.

Second, physician has to assess parameter values of heart-aspecific gastric Reflex (6-7).

In health (Figure 5), digital pressure of “mean” intensity, applied upon right (and left) atrium and ventricle skin projection area, brings about aspecific gastric Reflex after a latency time of 8 sec.

exactly, showing a duration of  $> 3 \text{ sec.} < 4 \text{ sec.}$ , indicating a physiological local Microcirculatory Functional Reserve (6-18).

## IL RIFLESSO GASTRICO ASPECIFICO

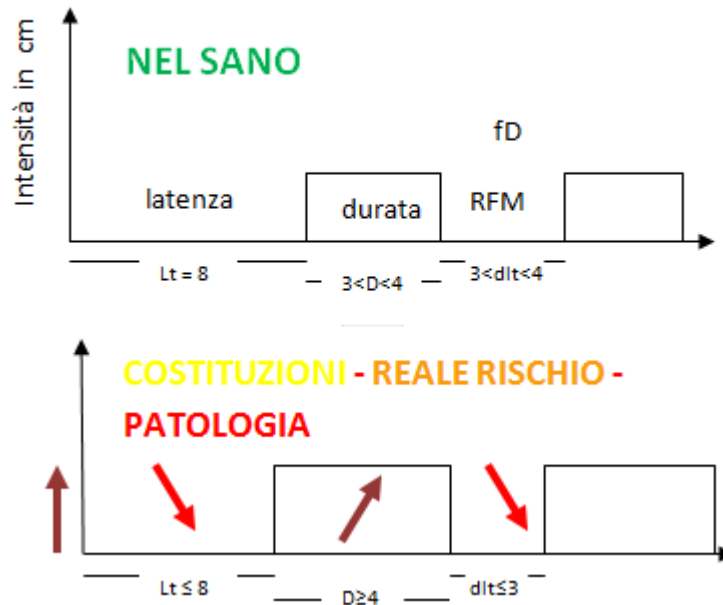


Figure 5

On the contrary, in diseased individual, involved by ARVD/C latency time appears either normal (NN = 8 sec.; NN stands for normal basal value) or shorter in inverse relation to the seriousness of underlying heart disorder. Importantly, the reflex duration results 4 sec. or more (NN < 4 sec.), indicating the impairment of Microcirculatory Functional Reserve of right atrium and right ventricle (6, 7, 11, 13).

Third, this manoeuvre plays a key role in bedside recognising heritable alteration of the free wall of the right ventricle, with fibro-fatty replacement of the right ventricular myocardium, where is a partial or near-complete substitution of myocardium with fatty tissue and ventricle enlargement. It involves predominantly the apical and infundibular regions of the RV. The left ventricle and ventricular septum are usually spared.

QBS signs, analogously to those we have described in Tako-Tsubo cardiomyopathy (18), are really characteristic and useful regarding ARVD/C diagnosis.

In health, “intense” digital pressure upon a large artery (e.g., femoral artery at groin, sympathetic hypertonia) does not cause “simultaneously” enlargement of right atrium and ventricle.

On the contrary, in patients involved by ARVD/C, starting from the birth, under the identical experimental condition, above illustrated, physician observes “simultaneously” a significant increasing of right atrium and ventricle size by means of heart auscultatory percussion.

Only physicians skilled in Quantum Biophysical Semeiotics and Clinical Microangiology ([www.semeioticabiofisica.it](http://www.semeioticabiofisica.it)) are able to assess both vasomotility and vasomotion of coronary micro-vessels and coronary artery autonomous-autoctonus oscillations of well localised areas.

## **Conclusion.**

Standardized diagnostic criteria have been proposed by the Study Group on ARVD/C of the Working Group Myocardial and Pericardial Disease of the European Society of Cardiology and of the Scientific Council on Cardiomyopathies of the International Society and Federation of Cardiology (19). Until now, notoriously, the diagnosis of ARVD/C is based on presence of major and minor criteria that encompass structural, histologic, electrocardiographic, arrhythmic, and genetic factors. On the basis of this classification, diagnosis of ARVD/C is fulfilled in the presence of 2 major criteria, or 1 major plus 2 minor criteria, or 4 minor criteria from different groups. There is a general agreement that, although these guidelines represent a useful clinical approach to ARVD/C diagnosis, optimal assessment of diagnostic criteria requires prospective evaluation obtained by international registry from a large population (20). The phenotype of ARVD/C is probably broader than has been recognized to date, and minor electrocardiographic or RV structural abnormalities that overlap with normality may represent disease expression, particularly in context of proven disease within families (21).

To carry to End unexpected deaths brought about by ARVD/C, physicians need a clinical tool, reliable, easy to apply, not expensive and able to be used repeatedly in therapeutic monitoring on very large scale. The QBS method illustrated in this brief paper, termed as Morosini's Syndrome, is certainly paramount, as regards the bedside diagnosing ARVD/C since individual's birth.

Sergio Stagnaro\*

*Via Erasmo Piaggio, 23/8 – Riva Trigoso - Genova*

*email dottsergio@semeioticabiofisica.it*

Simone Caramel \*\*

*Via Doberdò, 3 – Fontane di Villorba - Treviso*

*email simonecaramel@yahoo.it*

## References.

- 1) Basso C, Thiene G, Corrado D, Angelini A, Nava A, Valente M. Arrhythmogenic right ventricular cardiomyopathy: dysplasia, dystrophy, or myocarditis? *Circulation* 1996; 94:983-991.
- 2) Corrado D, Fontaine G, Marcus FI, et al. Arrhythmogenic right ventricular dysplasia/cardiomyopathy: need for an international registry. *Circulation* 2000; 101:E101-E106.
- 3) Metzger J, de Chillou C, Cheriex E, Rodriguez LM, Smeets JL, Wellens HJ. Value of the 12-lead electrocardiogram in arrhythmogenic right ventricular dysplasia, and absence of correlation with electrocardiographic findings. *Am J Cardiol* 1993; 72:964-967. [MEDLINE]
- 4) Pinamonti B, Sinagra G, Camerini F. Clinical relevance of right ventricular dysplasia/cardiomyopathy (editorial). *Heart* 2000; 83:9-11.
- 5) Thiene G, Nava A, Corrado D, Rossi L, Pennelli N. Right ventricular cardiomyopathy and sudden death in young people. *N Engl J Med* 1988; 318:129-133. [MEDLINE]
- 6) Sergio Stagnaro (2012). Caotino's and Gentile's Signs in bedside diagnosing CAD Inherited Real Risk and Myocardial Infarction, even initial or silent. Patho-physiology and Therapy. *Lectio Magistralis. III Congress of SISBQ, 9-10 June, 2012, Porretta Terme (Bologna)Italy.* [www.sisbq.org](http://www.sisbq.org). [http://www.sisbq.org/uploads/5/6/8/7/5687930/presentazione\\_stagnaro\\_it.pdf](http://www.sisbq.org/uploads/5/6/8/7/5687930/presentazione_stagnaro_it.pdf)
- 7) Stagnaro-Neri M., Stagnaro S. *Introduzione alla Semeiotica Biofisica. Il Terreno Oncologico.* Ed. Travel Factory, Roma, 2004. <http://www.travelfactory.it/> semeiotica\_biofisica.htm
- 8) Stagnaro Sergio. New bedside way in Reducing mortality in diabetic men and women. *Ann. Int. Med.* 2007. <http://www.annals.org/cgi/eletters/0000605-200708070-00167v1>
- 9) Stagnaro S. Epidemiological evidence for the non-random clustering of the components of the metabolic syndrome: multicentre study of the Mediterranean Group for the Study of Diabetes. *Eur J Clin Nutr.* 2007 Feb 7; [MEDLINE]
- 10) Stagnaro S. Newborn-pathological Endoarteriolar Blocking Devices in Diabetic and Dislipidaemic Constitution and Diabetes Primary Prevention. [www.fce.it](http://www.fceonline.it/docs/stagnaro.pdf), <http://www.fceonline.it/docs/stagnaro.pdf>
- 11) Stagnaro-Neri M., Stagnaro S., Deterministic Chaos, Preconditioning and Myocardial Oxygenation evaluated clinically with the aid of Biophysical Semeiotics in the Diagnosis of ischaemic Heart Disease even silent. *Acta Med. Medit.* 13, 109, 1997.
- 12) Sergio Stagnaro and Simone Caramel (2012) Quantum Biophysical Semeiotic Bedside Diagnosis of Tako-Tsubo Cardiomyopathy. The central Role played by CAEMH-Dependent GERD in precipitating the transient cardiac Dysfunction. [www.sisbq.org](http://www.sisbq.org), *Journal of Quantum Biophysical Semeiotics*, <http://www.sisbq.org/uploads/5/6/8/7/5687930/takotsubo.pdf>. ; <http://stagnaro-wwwsemeioticabiofisica.it.blogspot.com/2012/02/quantum-biophysical-semeitic-bedside.html>
- 13) Stagnaro Sergio. Role of Coronary Endoarterial Blocking Devices in Myocardial

Preconditioning - c007i. Lecture, V Virtual International Congress of Cardiology.  
<http://www.fac.org.ar/qcvc/llave/c007i/stagnaros.php>

14) Stagnaro Sergio. CAD Inherited Real Risk, Based on Newborn-Pathological, Type I, Subtype B, Aspecific, Coronary Endoarteriolar Blocking Devices. Diagnostic Role of Myocardial Oxygenation and Biophysical-Semeiotic Preconditioning. [www.athero.org](http://www.athero.org), 29 April, 2009  
<http://www.athero.org/commentaries/comm907.asp>

15) Sergio Stagnaro and Simone Caramel (2012). Allegra's\* Syndrome plays a central Role in bedside clinical Diagnostics. [www.sisbq.org](http://www.sisbq.org), *Journal of Quantum Biophysical Semeiotics*,  
<http://www.sisbq.org/uploads/5/6/8/7/5687930/allegrassyndrome.pdf>

16) Sergio Stagnaro and Simone Caramel (2012) Quantum Biophysical Semeiotics Microcirculatory Theory of Arteriosclerosis – [www.sisbq.org](http://www.sisbq.org), *Journal of Quantum Biophysical Semeiotics*, [http://www.sisbq.org/uploads/5/6/8/7/5687930/ats\\_qbs\\_mctheory.pdf](http://www.sisbq.org/uploads/5/6/8/7/5687930/ats_qbs_mctheory.pdf)

17) Sergio Stagnaro (2012). Valutazione Semeiotico-Biofisico-Quantistica dell'Attività Funzionale dei Sistemi Biologici. Il Ruolo dei Dispositivi Endoarteriolar di Blocco, fisiologici e neoformati-patologici tipo I, sottotipo a) e b). <http://www.sisbq.org/libri-e-articoli.html>, e-book,  
[http://www.sisbq.org/uploads/5/6/8/7/5687930/valutazione\\_attivit\\_biolog\\_2012.pdf](http://www.sisbq.org/uploads/5/6/8/7/5687930/valutazione_attivit_biolog_2012.pdf)

18) Sergio Stagnaro and Simone Caramel (2012) Quantum Biophysical Semeiotic Bedside Diagnosis of Tako-Tsubo Cardiomyopathy. The central Role played by CAEMH-Dependent GERD in precipitating the transient cardiac Dysfunction. [www.sisbq.org](http://www.sisbq.org), *Journal of Quantum Biophysical Semeiotics*, <http://www.sisbq.org/uploads/5/6/8/7/5687930/takotsubo.pdf>. ;  
<http://stagnaro-wwwsemeioticabiofisica.it.blogspot.com/2012/02/quantum-biophysical-semeitic-bedside.html>

19) McKenna WJ, Thiene G, Nava A, Fontaliran F, Blomstrom-Lundqvist C, Fontaine G, Camerini F. Diagnosis of arrhythmogenic right ventricular dysplasia/cardiomyopathy. *Br Heart J*. 1994;71:215–218.

20) Baraka M, Fontaliran F, Frank R, Fontaine G. Value of task force criteria in the diagnosis of arrhythmogenic right ventricular dysplasia-cardiomyopathy. *Herzschr Elektrophys*. 1998;9:163–168.

21) Corrado D., Fontaine G., Marcus F.I., et al. *Circulation*. 2000;101:e101-e106: Arrhythmogenic Right Ventricular Dysplasia/Cardiomyopathy